# Nutritional Diseases 51

*Bernice Y. Kwong, Lucero Noguera-Morel, Stephanie Ann McLeish and Chad M. Hivnor*

## Key features

- Deficiencies in macronutrients (carbohydrates, fats, proteins) and micronutrients (vitamins, essential trace minerals) can affect any organ system, including the skin, which may provide clues to the diagnosis
- Severe acute malnutrition manifests as two classic protein–energy malnutrition syndromes: kwashiorkor and marasmus
- In addition to inadequate oral intake, there are secondary causes of nutritional deficiencies including intestinal malabsorption due to medical conditions, medications, and surgical procedures as well as increased nutritional demand due to severe illnesses (e.g. late-stage metastatic carcinoma, systemic infection)
- Vitamin and trace element deficiencies can lead to a wide range of mucocutaneous findings, from follicular keratoses to periorificial erosions to poor wound healing
- Obesity can be associated with high-calorie malnutrition and multiple skin changes ranging from acanthosis nigricans to lipodermatosclerosis

## INTRODUCTION

Proper nutrition is fundamental to human life. From fetal development to adulthood, proper nutrition is essential for survival, physical growth, mental development, productivity, and overall health[1]. Deficiency of one isolated nutrient is rare, as individuals are usually deficient in multiple nutrients at the same time. In general, nutrients are categorized as macronutrients (carbohydrates, proteins, and fats) or micronutrients (vitamins and minerals). Most people who suffer from nutritional deficiencies live in low-income countries. However, there are certain conditions that predispose individuals from high-income countries to develop nutritional deficiencies, such as alcohol use disorder, intestinal malabsorption, anorexia nervosa or bulimia, restrictive diets, medications, and chronic or severe acute illnesses.

Nutrients require a process of ingestion, digestion, absorption, and circulation plus subsequent metabolism in order to be beneficial. When any one of these steps is disrupted, or if energy expenditure is increased, clinical manifestations may appear due to insufficient nutrition.

## EPIDEMIOLOGY AND PATHOGENESIS

In low-income countries, malnutrition stems primarily from inadequate ingestion of all macronutrients as well as many micronutrients (Fig. 51.1). The World Health Organization (WHO) has estimated that worldwide, ~45% of deaths in children <5 years of age are due directly or indirectly to the multisystem ramifications of undernutrition. In industrialized regions of the world, malnutrition is directly linked to the per capita gross national product; if a country has a per capita income that is less than US$300 per year, endemic malnutrition is likely, especially in infants and young children.

At the same time, a global epidemic of obesity has emerged within industrialized countries, with increasing rates of death due to cardiovascular disease and diabetes mellitus[1]. Excessive consumption of foods high in calories but low in nutrients can lead to obese patients who lack essential vitamins and minerals. This is supported by a study in which 57% of morbidly obese patients undergoing preoperative assessment for bariatric surgery were found to have a deficiency in at least one micronutrient[2].

Restrictive diets, including those based upon real or perceived need (e.g. food allergies, weight loss, health benefit), psychiatric illness (e.g. anorexia nervosa) or mental impairment (e.g. substance use disorder), also disrupt the intake of appropriate nutrients and can result in malnutrition.

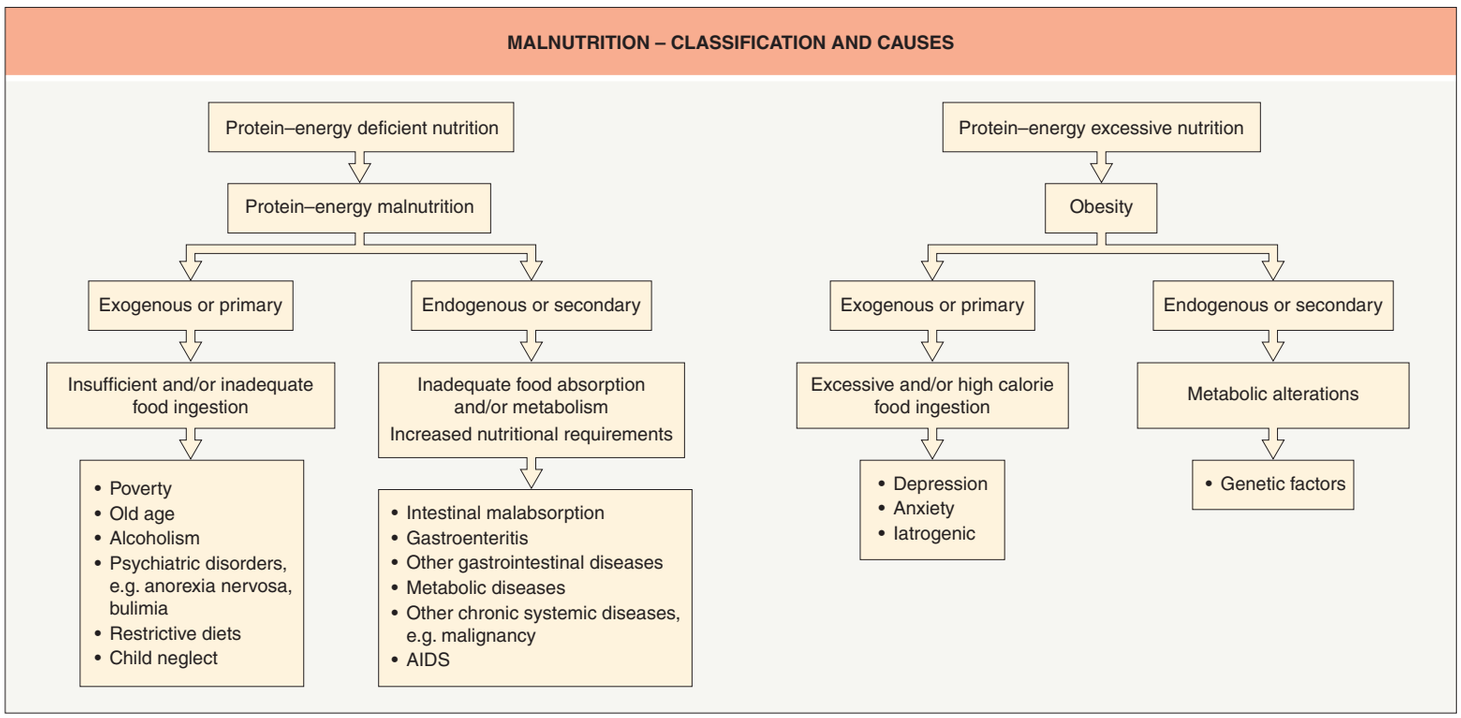


**Fig. 51.1 Malnutrition – classification and causes.** *Courtesy Ramón Ruiz-Maldonado, MD.*



Downloaded for Anonymous User (n/a) at Egyptian Knowledge Bank from ClinicalKey.com by Elsevier on March 10, 2024. For personal use only. No other uses without permission. Copyright ©2024. Elsevier Inc. All rights reserved.

In addition to a diet inadequate in the quantity and/or quality of macro- and micronutrients (i.e. primary causes), there are medical conditions that can lead to a functional malnutrition, i.e. secondary causes. The latter include an increase in metabolic requirements (e.g. severe infections, prolonged hospitalization) and/or a decrease in the transport and utilization of nutrients (e.g. intestinal malabsorption, bariatric surgery, medications). Malnutrition is also seen in individuals with late-stage internal malignancies and advanced AIDS as well as following allogeneic hematopoietic stem cell transplantation as a result of conditioning and/or gastrointestinal graft-versus-host disease (Table 51.1)[3].

## CLINICAL FEATURES

Weight-for-height scores and height-for-age scores are utilized to evaluate malnutrition; scores are compared to the standard deviations (SD) from the median value for the reference population. An individual is considered to have moderate malnutrition if the scores are between the 2nd to 3rd (lower) SD and severe malnutrition if below the 3rd SD, with or without symmetrical edema[4]. Cutaneous manifestations in part reflect the fact that epidermal maturation (from basal cell layer to stratum corneum) occurs over a period of 10–14 days. Deficiencies,

| CHARACTERISTICS OF SEVERE ACUTE MALNUTRITION (PROTEIN–ENERGY MALNUTRITION) AND ESSENTIAL FATTY ACID DEFICIENCY | | | |
|---|---|---|---|
| | **Severe acute malnutrition (protein–energy malnutrition)** | | |
| | **Marasmus** | **Kwashiorkor** | **Essential fatty acid deficiency[45,46]** |
| Causes | • Prolonged insufficient energy (caloric) intake<br>• Develops over months to years<br>• Primary causes: reduced caloric intake (poverty, alcoholism, substance use disorder, other psychiatric disorders, restrictive diets, child or elderly neglect/abuse)<br>• Secondary causes: reduced absorption (intestinal malabsorption, chronic diarrhea), increased caloric demand (malignancies), chronic systemic diseases (e.g. hepatic failure, end-stage renal disease), AIDS*, metabolic disorders) | • Insufficient nutritional intake with adequate caloric intake during periods of stress lasting a few weeks or more<br>• Diets consisting primarily of rice or rice-based beverages (e.g. "rice milk") for perceived milk intolerance, restrictive low-protein fad diets<br>• Other causes: protein-losing enteropathies, malabsorption (e.g. cystic fibrosis), extensive gastrointestinal surgeries, HIV disease*, severe illnesses/prolonged hospitalizations | • Protein–energy malnutrition<br>• Gastrointestinal disorders/surgeries causing severe fat malabsorption<br>• Long-term parenteral nutrition without lipid supplementation<br>• Diets extremely low in fat<br>• Nephrotic syndrome<br>• Inborn errors of metabolism, e.g. deficiency of fatty acid desaturase 2 (FADS2; also referred to as delta (6) desaturase) |
| Cutaneous features | • Dry, thin, pale, lax and wrinkled skin<br>• Occasionally, fine scaling and hyperpigmentation (Fig. 51.3)<br>• Follicular hyperkeratosis and folliculitis in adults<br>• Ulcerations<br>• Excess of lanugo-like hair<br>• Thin hair that grows slowly and falls out readily<br>• Impaired growth of nails and fissured nails<br>• Purpura (Fig. 51.4) | • Dyschromia is a common finding<br>• Pallor due to distention of the skin and loss of pigment<br>• Hypopigmentation following abrasions; ulcerations and hyperpigmentation in areas subject to trauma<br>• Superficial desquamation in mild cases ("enamel paint spots"), but in severe cases large areas of erosion ("flaky paint") (Fig. 51.6)<br>• Other cutaneous signs include erythema, thinning, petechiae, ecchymoses, and purpura<br>• Hair is sparse, dry, lusterless and brittle with a reddish tinge; bands of light and dark coloration ("flag sign") reflect intermittent periods of malnutrition; positive gentle hair pull test<br>• Nails are soft and thin<br>• Mucosal lesions: cheilitis, xerophthalmia, and vulvovaginitis | • Dry, scaly, and leathery skin with underlying erythema<br>• Intertriginous erosions<br>• Alopecia and more lightly pigmented hair<br>• Increase in transepidermal water loss<br>• Petechiae |
| Systemic features | • Starved appearance but alert<br>• Reasonably preserved responsiveness to short-term stress<br>• Bradycardia, hypotension, and hypothermia<br>• Loss of subcutaneous fat and muscle (Fig. 51.3)<br>• "Monkey facies" or an aged appearance (due to loss of buccal fat pads)<br>• Suppression of growth | • Relatively well-nourished appearance<br>• Edema or even anasarca (Fig. 51.5)<br>• Apathy, anorexia, irritability<br>• Failure to thrive (retardation of growth and mental development)<br>• Superimposed bacterial and fungal (e.g. candidal) infections<br>• Bilateral parotitis, hepatomegaly, diarrhea, loss of muscle mass | • Growth failure<br>• Poor wound healing<br>• Impaired reproduction<br>• Abnormal liver and kidney function tests<br>• Capillary fragility<br>• Increased susceptibility to infections<br>• Neurologic damage |
| Lab findings and diagnostic criteria | • Triceps skin-fold <3 mm<br>• Mid-arm muscle circumference <15 cm<br>• Creatinine–height index <60% of standard<br>• Low plasma zinc levels<br>• Epidermal acanthosis, confluent hyperkeratosis, pallor of upper layers of the epidermis (missing in later lesions)<br>• Most hair bulbs are in the telogen phase<br>• Abundant broken hairs | • At least one of the following: poor wound healing, decubitus ulcers, or skin breakdown<br>• Anergy<br>• Hypoalbuminemia (<2.5 g/dl)<br>• Total iron-binding capacity <200 mcg/dl<br>• Peripheral lymphocyte count <1500/mcl<br>• Steatohepatitis<br>• Decreased number of anagen hair follicles and increased number of telogen follicles<br>• Structural abnormalities in anagen follicles – severe atrophy, shaft constriction, depletion of pigment<br>• Exclude nephrotic syndrome | • Low plasma levels of linoleic and linolenic acids<br>• Accumulation of 5,8,11-eicosatrienoic acid<br>• Triene (eicosatrienoic acid) : tetraene (arachidonic acid) ratio >0.4<br>• Elevated levels of palmitoleic and oleic acids<br>• Anemia, thrombocytopenia<br>• Orthokeratotic hyperkeratosis, acanthosis with hypergranulosis, atrophic sebaceous glands, and papillary dermal vasodilation with a mixed cell infiltrate (in rat models)<br>• Steatohepatitis |

**Table 51.1 Characteristics of severe acute malnutrition (protein–energy malnutrition) and essential fatty acid deficiency.**



Downloaded for Anonymous User (n/a) at Egyptian Knowledge Bank from ClinicalKey.com by Elsevier on March 10, 2024. For personal use only. No other uses without permission. Copyright ©2024. Elsevier Inc. All rights reserved.

| CHARACTERISTICS OF SEVERE ACUTE MALNUTRITION (PROTEIN–ENERGY MALNUTRITION) AND ESSENTIAL FATTY ACID DEFICIENCY | | | |
|---|---|---|---|
| | **Severe acute malnutrition (protein–energy malnutrition)** | | |
| | **Marasmus** | **Kwashiorkor** | **Essential fatty acid deficiency**[45,46] |
| Treatment | • Treat or prevent hypothermia, dehydration, hypoglycemia, and electrolyte imbalances<br>• Treat infections<br>• *Slowly* replace proteins and calories, allowing for readaptation of metabolic and intestinal functions<br>• Supplementation with linoleic acid and zinc<br>• Monitor for hypophosphatemia and cardio-respiratory failure (associated with overly aggressive nutritional replacement)<br>• Address underlying diseases, social issues | • Aggressive nutritional support is indicated to rapidly restore metabolic balance; correction of any electrolyte disturbances or hypoglycemia<br>• Institute diet with adequate protein and caloric intake; supplementation with minerals and vitamins is required as patients often have multiple nutritional deficiencies<br>• Identify and attempt to treat underlying cause(s), including bacterial and parasitic diseases<br>• Topical moisturizers as needed | • Essential fatty acid replacement, depending upon severity<br>• Correction of coexisting nutritional deficiencies |
| Prognosis | • 10% mortality, often secondary to diarrhea or pneumonia<br>• Mortality rate related to underlying disease(s) | • Prognosis in adult patients is poor, even with aggressive nutritional support<br>• In children, a lesser degree of stress is required to precipitate the disorder, so it is less foreboding<br>• Severe, relapsing cases and those with coexistent HIV disease have a high mortality rate<br>• Death usually occurs due to overwhelming infection despite antibiotic treatment | • Prognosis depends on the severity and coexistence of other nutritional deficiencies<br>• Depends on awareness of this entity |
| *HIV disease is more often associated with marasmus than with kwashiorkor. | | | |

**Table 51.1 Characteristics of severe acute malnutrition (protein–energy malnutrition) and essential fatty acid deficiency.** AIDS, acquired immunodeficiency syndrome; HIV, human immunodeficiency virus.

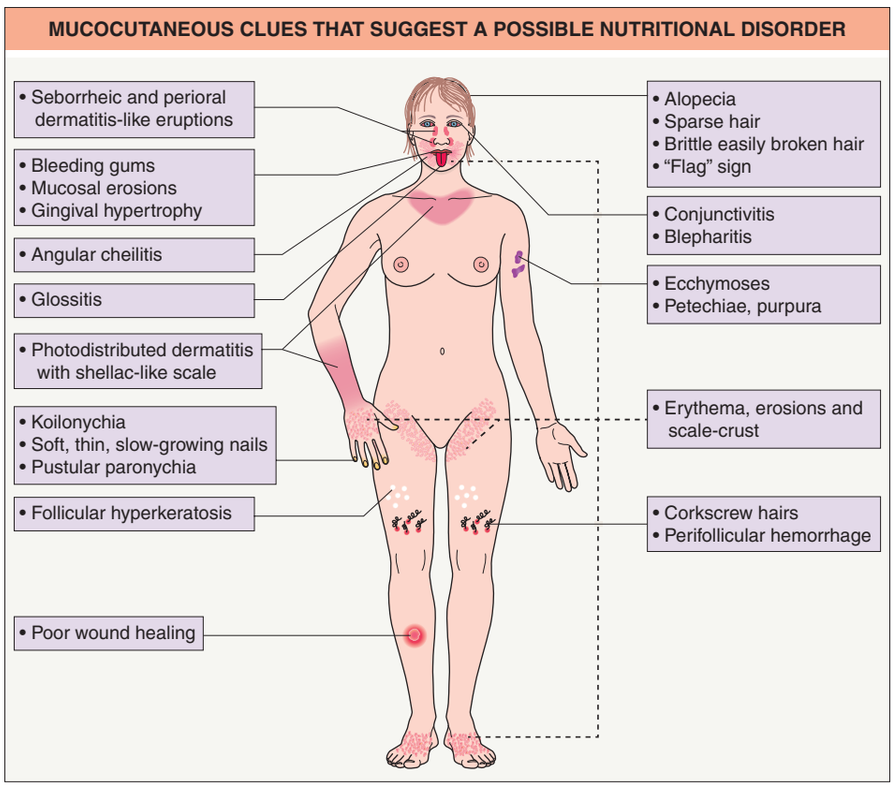


**Fig. 51.2 Mucocutaneous clues that suggest a possible nutritional disorder.** Risk factors are similar to those outlined for marasmus in Table 51.1. *Courtesy Karynne O. Duncan, MD.*

especially of macronutrients, can interfere with this process, resulting in skin that is dry and thin in appearance with associated epidermal atrophy. Prolonged deficiency can reduce both protein production, including that of dermal collagen and muscle, and the amount of subcutaneous fat. As a result, patients may develop dermal atrophy, muscle wasting, and/or lax skin.

Additional clinical findings of marasmus and kwashiorkor, such as dyschromia (hypo- and hyperpigmentation), desquamation, and erosions, are reviewed in Table 51.1. Patients may also have cutaneous manifestations from a deficiency in one or more micronutrients, and these are outlined in Table 51.2[5–10]. Mucocutaneous clues to the possibility of a nutritional deficiency are summarized in Fig. 51.2.

## Protein–Energy Malnutrition

Worldwide, protein–energy malnutrition (or undernutrition) is the most prevalent nutritional deficiency. The two major forms of severe acute malnutrition (SAM) are: (1) marasmus, also referred to as wasting or malnutrition without edema (Figs. 51.3 & 51.4); and (2) kwashiorkor, also referred to as edematous malnutrition. Patients with marasmic kwashiorkor have features of both wasting and edema. According to the WHO, on a global basis, SAM affects almost 20 million young children (<5 years of age).

*Marasmus* (SAM *without* edema) can occur in individuals of all ages and results from a prolonged inadequate intake of total calories (energy).



Downloaded for Anonymous User (n/a) at Egyptian Knowledge Bank from ClinicalKey.com by Elsevier on March 10, 2024. For personal use only. No other uses without permission. Copyright ©2024. Elsevier Inc. All rights reserved.

These patients frequently develop recurrent infections due to their inability to mount a normal immune response.

*Kwashiorkor* (SAM *with* edema) is a more acute form of childhood and adult protein–energy malnutrition (see Table 51.1). A characteristic finding is peripheral edema or even anasarca in association with hypoalbuminemia (Fig. 51.5). One consequence of this edema is a body weight that is higher than is seen with marasmus, and it may be 60%–80% of expected weight (rather than <40%). Some patients will have overlapping features of both disorders and this is referred to as marasmic kwashiorkor[11]. In at-risk populations, kwashiorkor can develop after a child is weaned from breast milk and begins a diet rich in carbohydrates but deficient in protein. In addition to peripheral edema, patients with kwashiorkor also develop desquamation and erosions that have been likened to "enamel paint" and "flaky paint" (Fig. 51.6).

Based upon clinical observations, it was thought that kwashiorkor was due to a relative deficiency in protein *intake*. However, more recently, this proposed pathogenesis has been questioned based upon several findings. For example, protein intake was found to be similar in a group of children, irrespective of whether they had marasmus or kwashiorkor[12]. In addition, kwashiorkor can develop within just a few weeks of an acute, life-threatening illness. A current theory is that kwashiorkor is related to physiologic stresses secondary to an acute or chronic illness (including infections), with the stress leading to an increase in protein and energy requirements at a time when intake is frequently limited[13]. This would help to explain why kwashiorkor often occurs in the setting of an acute illness superimposed upon a chronic state of milder malnutrition. It is hypothesized that the stress of the acute illness blocks the protein-sparing response that is normally in effect during states of starvation. There is also increasing evidence for a relationship between the gut microbiome and the development of malnutrition, including kwashiorkor. A deficiency of anti-inflammatory taxa and an increase in inflammogenic bacteria were noted in the gut microbiome of affected children[14,15].

Both kwashiorkor and marasmus can have secondary causes such as "rice milk" diets or chronic diarrhea (see Table 51.1). The cutaneous and systemic abnormalities associated with primary protein–energy malnutrition are often reversible following nutritional therapy. However, if the malnutrition is prolonged, this may preclude normal physical and/or mental development[11].

Severe acute malnutrition is less common in adults, but can occur in the setting of critical illnesses requiring hospitalization, where catabolism exceeds anabolism. Protein loss and hypoalbuminemia may also develop in patients with exfoliative erythroderma (see Ch. 10). Delayed wound healing is one of the important consequences of protein deficiency.

## Essential Fatty Acid Deficiency

Essential fatty acids (EFAs) are unsaturated fatty acids that must be obtained from an exogenous source because they cannot be synthesized by the human body. Linoleic acid and alpha-linolenic acid, which

**Fig. 51.3 Marasmus.** This child is emaciated and has obvious hyperpigmentation. Both erosions and desquamation are present on the scalp. *Courtesy Ramón Ruiz-Maldonado, MD.*

**Fig. 51.5 Kwashiorkor.** There is intense edema of the buttocks and lower extremities in addition to areas of erythema with erosions and desquamation. The edema is a reflection of hypoalbuminemia. *Courtesy Ramón Ruiz-Maldonado, MD.*

**Fig. 51.4 Marasmus.** Multiple sites of purpura are seen. *Courtesy Ramón Ruiz-Maldonado, MD.*

**Fig. 51.6 Kwashiorkor.** Edema, ulceration, and shellac-like scale that resembles peeling paint.



Downloaded for Anonymous User (n/a) at Egyptian Knowledge Bank from ClinicalKey.com by Elsevier on March 10, 2024. For personal use only. No other uses without permission. Copyright ©2024. Elsevier Inc. All rights reserved.

represent omega-6 and omega-3 fatty acids, respectively, are major types of EFAs. These fatty acids are present in plant oils (e.g. canola, flaxseed, soybean) and in fish oils. EFAs have multiple functions, both structural and synthetic, including prostaglandin formation, phospholipid membrane integrity, energy storage, and proper lamellar granule formation. Humans can convert linoleic acid into arachidonic acid. From 15% to 30% of the skin's fatty acids are EFAs and cutaneous as well as systemic manifestations of EFA deficiency are outlined in Table 51.1.

While an isolated deficiency of EFAs is uncommon, it may occur following parenteral nutrition without lipid supplementation and with overly aggressive low-fat diets. In most instances, however, EFA deficiency is associated with other nutritional deficiencies. The presence of decreased plasma levels of linoleic and linolenic acids plus increased levels of eicosatrienoic acid (normally undetectable) establishes the diagnosis of EFA deficiency (see Table 51.1).

Data from the American Heart Association suggest that obtaining 5%–10% of energy from omega-6 fatty acids (e.g. linoleic acid) reduces the risk of cardiovascular disease. However, there is still controversy regarding the recommended upper limit of consumption of EFAs, as epidemiologic studies suggest that an excess of linoleic acid may contribute to cardiovascular disease, cancer, and inflammation[16].

## Vitamins and Trace Elements

Micronutrients represent a diverse array of dietary components that are necessary to sustain health. The physiologic roles of micronutrients are as varied as their composition. Several micronutrients function as cofactors for enzymes, while others act as biochemical substrates or hormones; in addition, there are some whose function has not been well defined[5]. Under normal circumstances, the recommended average daily dietary intake for each micronutrient is measured in milligrams or even smaller quantities. This distinguishes micronutrients from macronutrients (carbohydrates, fats, proteins) as well as the macrominerals (calcium, magnesium, phosphorus)[5].

### *Vitamins*

Vitamins are required constituents of the human diet as they are essential for development and maintenance of bodily functions. However, they do not have a direct role as an energy source. Vitamins are categorized as either fat-soluble (A, D, E, K) or water-soluble (all others) (see Table 51.2). While none of the fat-soluble vitamins appear to serve as cofactors for enzymes, most of the water-soluble vitamins have this function[5]. In addition, symptomatic vitamin excess is more likely with fat-soluble vitamins (see below). Lastly, the use of vitamins

| VITAMIN DEFICIENCIES IN ADULTS AND CHILDREN | | | | | |
|---|---|---|---|---|---|
| **Vitamin** | **Clinical manifestations** | | | **Reference values** | **Replacement therapy** |
| | **Mucocutaneous** | **Systemic** | **Other** | | |
| **Fat-soluble vitamins – can easily accumulate and lead to toxicity if replaced in high doses for prolonged periods** | | | | | |
| **A** (retinol) | • Phrynoderma – follicular papules with central keratotic plug; favors extensor surfaces of extremities (Fig. 51.7) & buttocks<br>• Generalized xerosis<br>• Sparse, fragile hair | • Night blindness<br>• Xerophthalmia (dryness of the cornea & conjunctivae)<br>• Bitot spots (gray–white patches on the conjunctivae)<br>• Keratomalacia (softness of the cornea, sometimes with ulceration)[47]<br>• Stunted growth | • Increase in measles-related mortality (see Ch. 81)<br>• Increased susceptibility to and mortality from respiratory and diarrheal illnesses[47] | • Serum: LC–MS/MS for vitamin A levels<br>• Reference values (fasting):<br>0–6 yrs: 11–65 mcg/dl<br>7–12 yrs: 13–80 mcg/dl<br>13–17 yrs: 14–98 mcg/dl<br>≥18 yrs: 32–78 mcg/dl<br>• Supplementation recommended when <20 mcg/dl<br>• Severe deficiency when <10 mcg/dl | • Based on severity of ophthalmologic impairment<br>• Infants (<6 mos): 50 000 IU PO × 3 on days 1, 2, and at least 14<br>• Infants (6–12 mos): 100 000 IU PO × 3 doses (see above)<br>• Children >1 yr, men, postmenopausal women: 200 000 IU PO × 3 doses (see above)*<br>• Higher doses given if keratomalacia |
| **D**<br>**$D_2$:** ergocalciferol<br>**$D_3$:** cholecalciferol | None | • Muscle weakness<br>• Rickets in children<br>• Osteomalacia in adults | • Possible decrease in innate immunity (see Table 51.3)<br>• Possible increase in internal malignancies (e.g. colon, prostate) | • Total serum or plasma 25(OH) vitamin D is measured ($D_2$ plus $D_3$)<br>• Deficiency: <12 ng/ml (IU: <30 nmol/l)<br>• Insufficiency: 12–20 ng/ml (IU: 30–50 nmol/l)[20] | • For deficiency, 50 000 IU of vitamin $D_2$ or $D_3$ (preferred) PO once weekly × 6–8 weeks<br>• Maintenance dose is age-dependent (see text)<br>• For insufficiency, vitamin $D_3$ 800–1000 IU/day PO<br>• Plus 1 g/day of oral calcium if deficient |
| **E** (tocopherol) | None | • Ophthalmoplegia, ptosis<br>• Muscle weakness, ataxia, areflexia<br>• Pigmentary retinopathy | | • Serum: LC–MS/MS for vitamin E levels<br>• Reference values (fasting):<br>0–17 yrs: 3.8–18.4 mg/l<br>≥18 yrs: 5.5–17.0 mg/l<br>• Significant deficiency: <3.0 mg/l | • Children 200–300 mg/day PO<br>• Adults 800–1000 mg/day PO |
| **K**<br>**$K_1$:** phytonadione (source = diet)<br>**$K_2$:** menaquinone (source = gut bacteria) | Petechiae, purpura, ecchymoses, mucosal bleeding | • If severe hypoprothrombinemia, extensive hemorrhage at any body site<br>• Hemorrhagic disease of the newborn – infants not given vitamin K at birth plus inadequate diet or mother on medications which inhibit vitamin K function†,[47] | | • Elevated prothrombin time & INR<br>• Serum or plasma vitamin $K_1$ level is measured<br>• ≥18 yrs: 0.10–2.20 ng/ml versus 0.2–3.2 ng/ml | • Newborns: 0.5–1 mg sc or IM<br>• Children: 2 mg PO<br>• Adults: 5–10 mg PO<br>• IV or SC administration if emergency<br>• Intravenously in emergencies (risk of anaphylaxis)<br>• Fresh frozen plasma<br>• Doses for $K_1$ and $K_2$ similar |

**Table 51.2 Vitamin deficiencies in adults and children.**

*Continued*



Downloaded for Anonymous User (n/a) at Egyptian Knowledge Bank from ClinicalKey.com by Elsevier on March 10, 2024. For personal use only. No other uses without permission. Copyright ©2024. Elsevier Inc. All rights reserved.

| VITAMIN DEFICIENCIES IN ADULTS AND CHILDREN | | | | | |
|---|---|---|---|---|---|
| **Vitamin** | **Clinical manifestations** | | | **Reference values** | **Replacement therapy** |
| | **Mucocutaneous** | **Systemic** | **Other** | | |
| **Water-soluble vitamins – less likely to accumulate & lead to toxicity, but in high doses can lead to side effects, e.g. nephrolithiasis (vitamin C), hepatitis (niacin)** | | | | | |
| **C** (ascorbic acid) | • Spongy gingivae with bleeding & erosions<br>• Petechiae, ecchymoses<br>• Follicular hyperkeratosis, especially forearms, abdomen, & legs<br>• Corkscrew hairs (flattened & curled) with perifollicular erythema or hemorrhage (Fig. 51.8)<br>• Splinter hemorrhages<br>• Poor wound healing | • Subperiosteal hemorrhage with "pseudoparalysis", especially in children<br>• Arthralgias, joint swelling, edema<br>• Loose teeth<br>• Weakness, malaise, depression<br>• Vasomotor instability[47]<br>• In infants, hemorrhage into GI and GU tracts<br>• Anemia<br>• Impeded growth<br>• Cerebral & femoral sheath hemorrhages | • Many of the signs of *scurvy* are related to impaired collagen synthesis<br>• Fractures of cartilaginous matrix<br>• Positive Rumpel–Leede capillary fragility test (>20 petechiae/inch$^2$)[‡] | • Plasma: HPLC for ascorbic acid levels<br>• Conventional (fasting): 0.6–2.0 mg/dl<br>• <0.2 mg/dl = scurvy<br>• Absence of vitamin C in urine<br>• Leukocyte vitamin C is more accurate, but less accessible, assay; 0 mg/dL = scurvy; up to 7 mg/dL = deficiency | • Adults: 200–1000 mg/day PO (in divided doses)<br>• Children: 100–300 mg/day PO (in divided doses), then 100 mg PO once weekly<br>• Higher dosage (1–2 g/day) may decrease symptom duration<br>• IM or IV administration if required |
| **$B_1$** (thiamin; thiamine) | • Peripheral edema with possible secondary skin breakdown in "wet" beriberi<br>• Glossitis and glossodynia<br>• Angular cheilitis | • Early – fatigue, apathy, irritability, depression, drowsiness, anorexia, nausea, abdominal pain<br>• Late – peripheral neuropathy, weakness, cardiac failure, mental alterations, growth retardation<br>• Prolonged deprivation – meningismus, coma | • *Beriberi* is divided into "wet" and "dry" forms[¶]<br>• Korsakoff syndrome – amnesia, confabulation & peripheral neuropathy<br>• Wernicke encephalopathy – ophthalmoplegia, horizontal nystagmus, ataxia, confusion | • Whole blood thiamine diphosphate (TDP) level to assess active form of vitamin $B_1$ within erythrocytes<br>• TDP reference values (fasting): 70–180 nmol/l<br>• TDP level <70 nmol/l suggests deficiency | • 100 mg TID IV × several days, followed by 100 mg/day PO until complete recovery[41]<br>• Infantile beriberi: 5–20 mg IV[41] |
| **$B_2$** (riboflavin, lactoflavin) | • Angular cheilitis and dry fissured lips<br>• Glossitis – pebbly appearance, then atrophic with irregular denudation of papillae<br>• Pharyngitis<br>• In periorificial sites (head & neck, anogenital region) – painless scaly papules, ulcers, indolent fissures & seborrheic dermatitis-like lesions<br>• Conjunctivitis | • Superficial keratitis<br>• Photophobia<br>• Changes in iris (pigment clumping)<br>• Anemia due to bone marrow hypoplasia<br>• Intellectual disability in newborns | • In adults, *oro-oculo-genital syndrome* can occur, especially if there are additional B vitamin deficiencies | • Plasma: LC–MS/MS for riboflavin levels<br>• Reference values (fasting): 1–19 mcg/l<br>• Riboflavin level <1 mcg/l = deficiency; marginally low levels should also be corrected | • Riboflavin 3–10 mg/day PO<br>• In refractory cases, 2 mg IM TID |
| **$B_3$** (niacin, nicotinic acid) | • Photodistributed, well-demarcated erythema that becomes scarlet or hyperpigmented, with scale-crust; surface has shellac-like appearance (Fig. 51.9)<br>• "Casal necklace" – well-demarcated band around the neck<br>• Painful fissures of the palms & soles<br>• Peri-anal & oral inflammation & erosions<br>• Cheilitis and glossitis (atrophic, red)<br>• Vaginitis with ulceration | • Peripheral neuropathy with dysesthesias, including burning<br>• Esophagitis<br>• Anorexia<br>• Lassitude<br>• Dizziness<br>• Irritability, disorientation<br>• Abdominal pain<br>• Late – irritability, anxiety, apathy, diarrhea, nausea, dementia | • The classic triad of *pellagra* is dermatitis, diarrhea, and dementia, with the fourth "d" possibly death<br>• Because of large tissue stores, symptoms develop after months of niacin or tryptophan deficiency<br>• Other causes of pellagra include carcinoid syndrome, Hartnup disease, and medications, e.g. isoniazid | • Plasma; HPLC for niacin levels<br>• Reference values (fasting; mcg/ml):<br>Children <10 yrs<br>0.50–8.91 (normal)<br><0.50 (low)<br>Adults & children >10 yrs:<br>0.50–8.45 (normal)<br><0.50 (low) | • Nicotinamide (niacinamide) is the amide/water-soluble form of niacin<br>• Adults: nicotinamide 300 mg/day PO (in divided doses) × 3–4 weeks, then maintenance of niacin 15–20 mg/day PO<br>• Children: 10–50 mg every 6 hours PO until resolution of all signs and symptoms, then maintenance of 15–20 mg/day of niacin<br>• *For severe cases*, in adults: 50–100 mg five times/day IM or 25–100 mg twice daily IV (slow infusion); in children: up to 300 mg/day IV (slow infusion) |

**Table 51.2 Vitamin deficiencies in adults and children.**



Downloaded for Anonymous User (n/a) at Egyptian Knowledge Bank from ClinicalKey.com by Elsevier on March 10, 2024. For personal use only. No other uses without permission. Copyright ©2024. Elsevier Inc. All rights reserved.

| VITAMIN DEFICIENCIES IN ADULTS AND CHILDREN | | | | | |
|---|---|---|---|---|---|
| **Vitamin** | **Clinical manifestations** | | | **Reference values** | **Replacement therapy** |
| | **Mucocutaneous** | **Systemic** | **Other** | | |
| **$B_5$** (pantothenic acid) | • None | • Fatigue, headache & vomiting<br>• Hypoglycemia<br>• Paresthesias ("burning feet" syndrome) | • Rare | • Serum: microbiological assay<br>• Reference values (mcg/l):<br>≤1 yr: 3.45–845<br>1–10 yrs: 3.45–229.2<br>>10 yrs: 37–147 | Vitamin $B_5$ is ubiquitous in the food supply and deficiency rare |
| **$B_6$** (pyridoxine, pyridoxamine, pyridoxal) | • Periorificial seborrheic dermatitis-like lesions<br>• Angular cheilitis, stomatitis<br>• Glossitis – atrophic with ulceration<br>• Conjunctivitis<br>• Intertrigo | • Anorexia, nausea, vomiting<br>• Neurologic symptoms including peripheral neuropathy, somnolence, confusion, & seizures<br>• Sideroblastic anemia, eosinophilia, lymphopenia | | • LC–MS/MS for pyridoxal 5-phosphate levels<br>• Reference value (fasting): 5–50 mcg/l | • Pyridoxine 50–100 mg/day PO to prevent neuropathy[41]<br>• 100 mg/day IV in those with seizures[41] |
| **$B_7$** (biotin) | • Alopecia<br>• Seborrheic dermatitis of the scalp, face, and flexures<br>• Periorificial dermatitis (ocular, nasal, oral, anal)<br>• Cutaneous candidiasis<br>• Nummular eczema[47]<br>• Blepharitis, conjunctivitis<br>• Brittle nails<br>• Erythroderma in neonatal form<br>• Juvenile form may resemble acrodermatitis enteropathica | • Depression, lassitude<br>• Anorexia, nausea, & vomiting<br>• Paresthesias & hyperesthesias<br>• Hypotonia, muscle pain<br>• Developmental delay, hearing loss<br>• Seizures, ataxia<br>• Both forms fatal if not treated | • Neonatal form – holocarboxylase synthetase deficiency (see Fig. 51.13)<br>• Juvenile form – biotinidase deficiency<br>• Two forms have overlap; both autosomal recessive<br>• Metabolic acidosis, lactic acidosis, hyperammonemia | • White blood cells: levels of biotinylated carboxylases, e.g. 3-methylcrotonyl-CoA or propionyl-CoA carboxylases<br>• Serum: microbiological assay<br>• Reference values (pg/ml) for microbiologic assay:<br><12 yrs: 100–2460<br>≥12 yrs: 221–3004<br>• Increased urinary excretion of organic acids (e.g. 3-hydroxy-isovaleric acid, 3-hydroxyisovalerylcarnitine)<br>• Genetic analysis (see Fig. 51.13) | • Infants & children: 5–20 mg/day PO or IM<br>• Adults: 10–40 mg/day PO or IM |
| **$B_9$** (folic acid; folate) | • Cheilitis, glossitis, mucosal erosions and ulcerations<br>• Diffuse hyperpigmentation, with accentuation in sun-exposed sites | • Megaloblastic anemia (macrocytosis plus hypersegmented neutrophils is pathognomonic)[47]<br>• Weakness secondary to anemia<br>• Neuropsychiatric symptoms due to impaired synthesis of myelin | • While folate can reverse the megaloblastic anemia of $B_{12}$ deficiency, it cannot reverse the neurologic degeneration | • *Serum* folate levels: <4 mcg/l suggests folate deficiency<br>• *RBC* folate levels: 140–628 ng/ml in packed RBCs<br>• IU: 317–1422 nmol/l in packed RBCs | • Replace folate and exclude $B_{12}$ deficiency<br>• Folate 1 mg TID PO, followed by 1 mg/day<br>• Folate 1–5 mg/day IV if acutely ill[41] |
| **$B_{12}$** (cyanocobalamin [CNCbl]) | • Diffuse or patchy hyperpigmentation, including flexural areas, dorsal hands and feet, palmar creases, soles, nails, oral cavity<br>• Glossitis with fissures of the oral mucosa (early sign prior to anemia)[48]<br>• Painful, red, swollen tongue<br>• Increased incidence of vitiligo, poliosis, and alopecia areata in patients with pernicious anemia | • Megaloblastic anemia due to altered folic acid metabolism<br>• Peripheral neuropathy, ataxia | • Pernicious anemia – decrease in gastric intrinsic factor<br>• Juvenile form – normal gastric acid secretion (in contrast to adult form)<br>• Use of Schilling test has been supplanted by serologic testing for anti-parietal cell and anti-intrinsic factor antibodies<br>• Associated autoimmune endocrinopathies | • Megaloblastic anemia with decreased serum $B_{12}$ levels<br>• Conventional: 200–835 pg/ml<br>• IU: 148–616 pmol/l<br>• More sensitive assay is serum levels of methylmalonic acid and homocysteine[§] | • Pernicious anemia: CNCbl 1000 mcg IM weekly × 4 weeks, then 1000 mcg PO, SL, or IM monthly<br>• If neurologic symptoms or severe anemia: CNCbl 1000 mcg IM twice weekly × 2 weeks then weekly × 2 months then monthly[41] |

*For women of reproductive age, 5000–10 000 IU/day × 4 weeks or 25 000 IU/week × 4 weeks unless severe keratomalacia.
†Medications that inhibit hepatic vitamin K epoxide reductase: warfarin, anticonvulsants, certain cephalosporins (containing side chains of N-methylthiotetrazole or methylthiadiazole), high-dose salicylates, and rifampin.
‡Following inflation of blood pressure cuff to a point between systolic and diastolic blood pressure for 5 minutes.
¶"Wet" beriberi derives its name from the edema that occurs secondary to cardiac failure, which can be high-output. In "dry" beriberi, neurologic manifestations predominate, e.g. peripheral neuropathy (sensory and motor), confusion, and nystagmus.
§Levels of both are increased early in vitamin $B_{12}$ deficiency; in folate deficiency, homocysteine levels are elevated but methylmalonic acid levels are normal.

**Table 51.2 Vitamin deficiencies in adults and children.** HPLC, high performance liquid chromatography; IM, intramuscularly; INR, international normalized ratio; IV, intravenously; LC–MS/MS, liquid chromatography–tandem mass spectrometry; mos, months; PO, orally; SC, subcutaneously; SL, sublingual; TID, three times per day; yrs, years. Adapted in part from refs 5–10.



Downloaded for Anonymous User (n/a) at Egyptian Knowledge Bank from ClinicalKey.com by Elsevier on March 10, 2024. For personal use only. No other uses without permission. Copyright ©2024. Elsevier Inc. All rights reserved.

| VITAMINS – SOURCES, FUNCTIONS AND RECOMMENDED PROPHYLACTIC DOSES | | | | |
|---|---|---|---|---|
| **Vitamin** | **Natural sources** | **Functions** | **Underlying etiologies/risk factors** | **Recommended daily intake (RDA in bold and *AI in italics*)** |
| **A** (retinol) | • Dietary pro-vitamin A (e.g. beta-carotene) from plant sources: leafy green vegetables, sweet potatoes, carrots<br>• Dietary preformed vitamin A (e.g. retinol) from animal sources: liver, milk, animal fats | • Normal vision<br>• Embryogenic development<br>• Physical growth<br>• Immune function<br>• Keratinocyte proliferation and differentiation<br>• If deficiency, squamous metaplasia of sebaceous and eccrine glands | • Minimal, if any, animal fats in diet<br>• Poverty<br>• Alcohol use disorder<br>• Anorexia nervosa<br>• Fad diets<br>• Fat malabsorption (e.g. gastric bypass, pancreatic insufficiency, inflammatory bowel disease, liver disease, cystic fibrosis) | • Measured in mcg of retinol activity equivalents (RAE)/day*<br>• Infants & children:<br>0–12 mos: *400–500 mcg*<br>1–8 yrs: **300–400 mcg**<br>9–13 yrs: **600 mcg**<br>• ≥14 yrs: **700–900 mcg**<br>• Pregnant women: **750–770 mcg**<br>• Lactating women: **1200–1300 mcg** |
| **D**<br>**$D_2$:** ergocalciferol<br>**$D_3$:** cholecalciferol | • Estimates of sources – 90% from UVB irradiation of the skin; 10% from food<br>• Plant sources ($D_2$; e.g. spinach, mushrooms exposed to UVR)<br>• Animal sources (e.g. cod liver oil, fatty fish such as salmon, herring, mackerel or tuna, fortified milk or yogurt) | • Induces antimicrobial peptide gene expression in keratinocytes, monocytes, NK cells, T cells, B cells, & neutrophils[17]<br>• Induces cathelicidins via the vitamin D receptor<br>• Helps absorption of ~85% of calcium and 40% of phosphorus via the gut<br>• Decreases proliferation of malignant cells & induces terminal differentiation[17] | • Risk factors include: breastfed infants, individuals with highly pigmented skin or limited sun exposure, advanced age, BMI >30 (fat sequesters vitamin D), living at extreme degrees of latitude[17]<br>• Generalized disorders of cornification<br>• Impaired absorption (e.g. gastrointestinal disease, gastric bypass, medications including phenytoin, corticosteroids, and stimulant laxatives)<br>• Organoid nevi | • Institute of Medicine recommendations:<br>0–12 mos: 400 IU<br>1–70 yrs: 600 IU<br>>71 yrs: 800 IU<br>• Many countries and institutions have their own recommendations regarding the appropriate dose of oral vitamin D per day |
| **E** (tocopherol) | • Ubiquitous in foods, so deficiency is rare | • Possible role in cellular homeostasis<br>• Antioxidant<br>• Interferes with vitamin K-dependent coagulation via unknown mechanism | • Long-term fat malabsorption (chronic cholestasis, small bowel resection, pancreatic insufficiency [absorption requires biliary and pancreatic secretions])[41]<br>• Genetic disorders (e.g. *TTPA* [alpha tocopherol transfer protein] pathogenic variants) | • Infants & children:<br>0–12 mos: *4–5 mcg*<br>1–8 yrs: **6–7 mcg**<br>9–13 yrs: **11 mcg**<br>• ≥14 yrs: **15 mcg**<br>• Pregnant women: **15 mcg**<br>• Lactating women: **19 mcg** |
| **K**<br>**$K_1$:** phytonadione (source = diet)<br>**$K_2$:** menaquinone (source = gut bacteria) | • $K_1$: green leafy vegetables & meat<br>• $K_2$: fermented foods & grass-fed animals<br>• Diet: ~50%<br>• Bacteria within large bowel: ~50% | • $K_1$: hepatic synthesis of coagulation factors II, VII, IX & X and proteins C & S<br>• $K_2$: regulates mineral localization (e.g. calcium)[49] | • Broad-spectrum antibiotics (reduce intestinal bacteria)<br>• Malabsorption syndromes<br>• Low-birthweight infants (inadequate intake, non-colonized colon, low hepatic stores, maternal medications†)<br>• Liver diseases, biliary atresia, cystic fibrosis<br>• Medications: cholestyramine, colestipol, colesevelam, orlistat, vitamin E, and inhibitors of vitamin K epoxide reductase†<br>• Total parenteral nutrition (TPN) | • Infants & children:<br>0–12 mos: *2–2.5 mcg*<br>1–8 yrs: *30–55 mcg*<br>9–13 yrs: *60 mcg*<br>14–18 yrs: *75 mcg*<br>• ≥19 yrs: *90–120 mcg*<br>• Pregnant & lactating women: *75–90 mcg* |
| **C** (ascorbic acid) | • Fresh fruits & vegetables | • Collagen formation<br>• Cofactor for several enzymes, e.g. lysyl hydroxylase<br>• Antioxidant<br>• Iron absorption<br>• Folate metabolism (folic acid to active form folinic acid) | • Alcohol and substance use disorders<br>• Fad diets<br>• Deficient intake for as few as 3 months can lead to scurvy[47]<br>• Increased requirements in the setting of febrile illnesses, malabsorption, iron deficiency, hemodialysis | • Infants & children:<br>0–12 mos: *40–50 mg*<br>1–8 yrs: **15–25 mg**<br>9–13 yrs: **45 mg**<br>14–18 yrs: **65–75 mg**<br>• ≥19 yrs: **75–90 mg**<br>• Pregnant women: **80–85 mg**<br>• Lactating women: **115–120 mg** |
| **$B_1$** (thiamine; thiamin) | • Yeast, cereals, liver, meat (pork), eggs, brown rice, vegetables including legumes | • Role in pyruvate metabolism (a source of energy generation)<br>• Cofactor in metabolism of carbohydrates, lipids, branched-chain amino acids[41] | • Starvation, alcohol use disorder<br>• Polished rice diet<br>• Hyperemesis gravidarum<br>• $B_1$-deficient diet (IV hyperalimentation or TPN) followed by high-carbohydrate diet exacerbates symptoms[41,‡]<br>• Hemodialysis, leukemia, rapidly growing carcinoma<br>• Urinary loss due to diuretics | • Infants & children:<br>0–12 mos: *0.2–0.3 mg*<br>1–8 yrs: **0.5–0.6 mg**<br>9–13 yrs: **0.9 mg**<br>14–18 yrs: **1–1.2 mg**<br>• ≥19 yrs: **1.1–1.2 mg**<br>• Pregnant & lactating women: **1.4 mg** |

**Table 51.3 Vitamins – sources, functions and recommended prophylactic doses.**



Downloaded for Anonymous User (n/a) at Egyptian Knowledge Bank from ClinicalKey.com by Elsevier on March 10, 2024. For personal use only. No other uses without permission. Copyright ©2024. Elsevier Inc. All rights reserved.

| VITAMINS – SOURCES, FUNCTIONS AND RECOMMENDED PROPHYLACTIC DOSES | | | | |
|---|---|---|---|---|
| **Vitamin** | **Natural sources** | **Functions** | **Underlying etiologies/risk factors** | **Recommended daily intake (RDA in bold and *AI in italics*)** |
| **$B_2$** (riboflavin; lactoflavin) | • Milk, cheese, eggs, fortified bread and cereals, yeast, lean meat, green vegetables | • Intracellular oxidation–reduction reactions | • Achlorhydria & GI malabsorption<br>• Alcohol use disorder<br>• Hypothyroidism<br>• Neonatal phototherapy for hyperbilirubinemia<br>• Low milk intake (e.g. due to lactose intolerance)<br>• Medications: chlorpromazine, probenecid, tricyclic antidepressants<br>• Exacerbated by respiratory infections | • Infants & children:<br>0–12 mos: *0.3–0.4 mg*<br>1–8 yrs: **0.5–0.6 mg**<br>9–13 yrs: **0.9 mg**<br>14–18 yrs: **1–1.3 mg**<br>• ≥19 yrs: **1.1–1.3 mg**<br>• Pregnant women: **1.4 mg**<br>• Lactating women: **1.6 mg** |
| **$B_3$** (niacin; nicotinic acid) | • Liver, lean pork, salmon, poultry, red meat, beans, milk, eggs<br>• Humans are able to synthesize niacin from tryptophan (an essential amino acid) | • Vital oxidation–reduction reactions<br>• Biosynthesis of epidermal lipids, e.g. ceramides | • Malnutrition<br>• Intestinal malabsorption<br>• Alcohol use disorder<br>• Diet limited to tryptophan-deficient corn (maize)[¶]<br>• Carcinoid syndrome[¶]<br>• Hartnup disease[¶]<br>• HIV infection, including those receiving isoniazid preventive therapy<br>• Medications: isoniazid > 6-mercaptopurine, azathioprine, 5-fluorouracil and drugs that inhibit conversion from tryptophan (e.g. phenobarbital, ethionamide)<br>• Deficiency of micronutrients (e.g. iron, riboflavin, pyridoxine) required for conversion from tryptophan | • Infants & children:<br>0–12 mos: *2–4 mg*<br>1–8 yrs: **6–8 mg**<br>9–13 yrs: **12 mg**<br>• ≥14 yrs: **14–16 mg**<br>• Pregnant women: **18 mg**<br>• Lactating women: **17 mg** |
| **$B_5$** (pantothenic acid) | • Synthesized in gut by bacterial flora | • Component of coenzyme A which plays major role in metabolism | • Protein–energy malnutrition | • Infants & children:<br>0–12 mos: *1.7–1.8 mg*<br>1–8 yrs: *2–3 mg*<br>9–13 yrs: *4 mg*<br>• ≥14 yrs: *5 mg*<br>• Pregnant women: *6 mg*<br>• Lactating women: *7 mg* |
| **$B_6$** (pyridoxine, pyridoxamine, pyridoxal) | • Widely distributed in nature<br>• Pyridoxine in plant food<br>• Pyridoxal and pyridoxamine in animal products<br>• All forms convert to the active form pyridoxal phosphate | • Cofactor for multiple enzymes involved in amino acid metabolism and conversion of linoleic acid to arachidonic acid<br>• Ceramide synthesis<br>• Gluconeogenesis & heme biosynthesis[41] | • Other vitamin or trace element deficiencies (metabolism of $B_6$ is dependent on riboflavin, niacin, & zinc)<br>• Medications: isoniazid, anticonvulsants, penicillamine, hydralazine, oral contraceptives, corticosteroids[41]<br>• Inflammatory bowel disease, uremia, & cirrhosis | • Infants & children:<br>0–12 mos: *0.1–0.3 mg*<br>1–8 yrs: **0.5–0.6 mg**<br>9–13 yrs: **1 mg**<br>14–18 yrs: **1.2–1.3 mg**<br>• ≥19 yrs: **1.3–1.7 mg**<br>• Pregnant women: **1.9 mg**<br>• Lactating women: **2 mg** |
| **$B_7$** (biotin) | • Liver is best source<br>• Other meats, egg yolks, yeast, soybeans, tomatoes<br>• Probably synthesized in gut by bacterial flora | • Essential cofactor for several carboxylases involved in cellular metabolism, e.g. of fatty acids<br>• Plays role in gluconeogenesis[47] | • Inborn error of metabolism (e.g. deficiencies of biotinidase or holocarboxylase synthetase)<br>• Inadequate diet<br>• Excessive raw egg white consumption[§]<br>• Chronic anticonvulsant therapy<br>• Pregnancy<br>• Chronic alcohol use disorder | • Infants & children:<br>0–12 mos: *5–6 mcg*<br>1–8 yrs: *8–12 mcg*<br>9–13 yrs: *20 mcg*<br>14–18 yrs: *25 mcg*<br>• ≥19 yrs: *25–30 mcg*<br>• Pregnant women: *30 mcg*<br>• Lactating women: *35 mcg* |
| **$B_9$** (folate; folic acid) | • Liver, green leaves, meat, milk, yeast, fortified foods<br>• Easily destroyed with cooking[47]<br>• Body stores are limited, so anemia can result after 4–5 months of deficient intake | • DNA synthesis | • Deficient diets<br>• *MTHFR* pathogenic variants<br>• Alcohol use disorder<br>• Intestinal malabsorption (inflammatory bowel disease, gastric bypass)<br>• Medications (which interfere with folate metabolism): methotrexate, sulfasalazine, pyrimethamine, phenytoin, trimethoprim | • Measured in mcg of dietary folate equivalents (DFEs)[‖]<br>• Infants & children:<br>0–12 mos: *65–80 mcg*<br>1–8 yrs: **150–200 mcg**<br>9–13 yrs: **300 mcg**<br>• ≥14 yrs: **400 mcg**<br>• Pregnant women: **600 mcg**<br>• Lactating women: **500 mcg** |

**Table 51.3 Vitamins – sources, functions and recommended prophylactic doses.**

*Continued*



Downloaded for Anonymous User (n/a) at Egyptian Knowledge Bank from ClinicalKey.com by Elsevier on March 10, 2024. For personal use only. No other uses without permission. Copyright ©2024. Elsevier Inc. All rights reserved.

| VITAMINS – SOURCES, FUNCTIONS AND RECOMMENDED PROPHYLACTIC DOSES | | | | |
|---|---|---|---|---|
| **Vitamin** | **Natural sources** | **Functions** | **Underlying etiologies/risk factors** | **Recommended daily intake (RDA in bold and *AI in italics*)** |
| **$B_{12}$** (cyano-cobalamin) | • Fish, shellfish, meat, dairy products, fortified foods<br>• Body stores are large, so development of deficiency requires 3–6 years of a deficient state | • DNA synthesis | • Strict vegetarianism/veganism<br>• Decrease in gastric intrinsic factor (pernicious anemia)<br>• Atrophic gastritis<br>• Intestinal malabsorption (e.g. celiac disease, inflammatory bowel disease)<br>• Gastrectomy, surgical resection of terminal ileum<br>• Overgrowth of intestinal bacteria<br>• Medications: metformin, H2 receptor antagonists, proton pump inhibitors, nitrous oxide<br>• Alcohol use disorder | • Infants & children:<br>0–12 mos: 0.4–0.5 mcg<br>1–8 yrs: **0.9–1.2 mcg**<br>9–13 yrs: **1.8 mcg**<br>• ≥14 yrs: **2.4 mcg**<br>• Pregnant women: **2.6 mcg**<br>• Lactating women: **2.8 mcg** |

*1 IU retinol = 0.3 mcg RAE; 1 IU β-carotene (dietary supplements) = 0.15 mcg RAE; 1 IU β-carotene (food) = 0.05 mcg RAE; 1 IU α-carotene or β-cryptoxanthin = 0.025 mcg RAE.
†Medications which inhibit vitamin K epoxide reductase in the liver: warfarin, anticonvulsants, certain cephalosporins (containing side chains of N-methylthiotetrazole or methylthiadiazole), high-dose salicylates, isoniazid, and rifampin.
‡Pyruvate and lactate, which interfere with carbohydrate metabolism, accumulate in a $B_1$-deficient state. A high-carbohydrate diet accentuates the pre-existing vitamin-deficient state, often precipitating a Wernicke or Korsakoff syndrome.
¶Tryptophan (an essential fatty acid) is a precursor of niacin. Tryptophan is deficient in maize, and millet interferes with tryptophan metabolism as it is high in leucine. In carcinoid syndrome, tryptophan is preferentially converted to serotonin instead of niacin, and in Hartnup disease, niacin deficiency is due to decreased intestinal absorption of tryptophan.
§Excessive consumption of raw egg whites (>20 eggs/day) leads to high levels of the protein avidin, which binds to biotin, rendering it biologically unavailable. Avidin is deactivated by cooking, while biotin remains intact.
‖1 mcg DFE = 1 mcg food folate; 1 mcg DFE = 0.6 mcg folic acid from fortified foods or dietary supplements consumed with foods; 1 mcg DFE = 0.5 mcg from dietary supplements taken on an empty stomach.

**Table 51.3 Vitamins – sources, functions and recommended prophylactic doses.** Recommended Dietary Allowance (RDA) is the average daily dietary intake that is sufficient for 97%–98% of healthy individuals in a group while the Adequate Intake (AI) is an approximation when an RDA cannot be determined. mos, months; MTHFR, methylenetetrahydrofolate reductase; UVB, ultraviolet B radiation; UVR, ultraviolet irradiation; yrs, years. Adapted in part from refs 5–7,9,10.

**Fig. 51.7 Phrynoderma of vitamin A deficiency.** Multiple clusters of follicular papules with central keratotic plugs. Histologically, keratinous plugs within follicles, hyperkeratosis, and atrophy of sebaceous glands are seen. It must be differentiated from pityriasis rubra pilaris and keratosis pilaris.

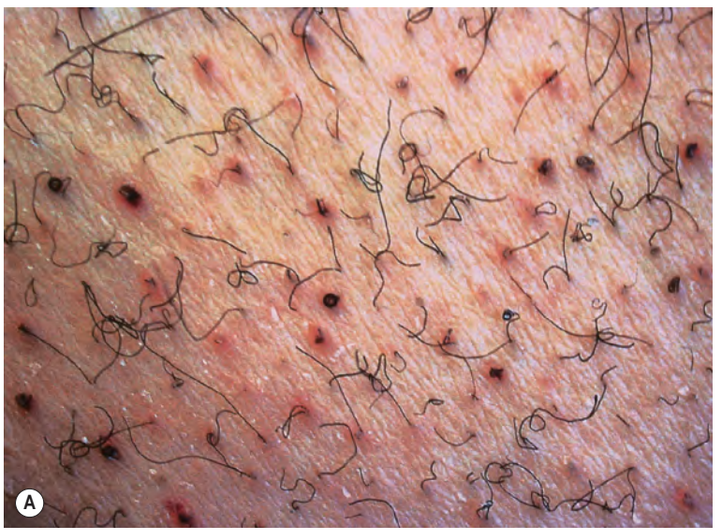

**Fig. 51.8 Scurvy. A** Corkscrew hairs and perifollicular hemorrhage on the lower extremities. **B** Gingivitis and gingival erosions. *B, Courtesy Jeffrey P. Callen, MD.*

as therapeutic interventions in dermatology includes topical vitamin D analogues for psoriasis[17] (see Ch. 129), oral nicotinamide for autoimmune blistering diseases and non-melanoma skin cancer prevention, oral or topical retinoids to treat acne and disorders of cornification (see Ch. 126), and topical vitamin C to try to reverse photodamage[18].

Tables 51.2 and 51.3 review the major fat- and water-soluble vitamins, including their functions and recommended daily dosages, as well as the risk factors for vitamin deficiencies and associated signs and symptoms[5–7,9,10].

## Vitamin excess

Excessive ingestion of vitamins most commonly occurs in individuals seeking potential (and often unproven) "anti-aging" or antineoplastic effects. High doses of fat-soluble vitamins may lead to harmful side effects, including hepatic toxicity, nephrolithiasis, and peripheral neuropathy (Table 51.4)[5–7]. They may also have unanticipated effects at high doses in certain populations. For example, in the β-Carotene and Retinol Efficacy Trial (CARET), a large cancer prevention trial, patients at high risk for lung cancer were given supplements containing β-carotene and vitamin A. Not only did these supplements fail to prevent lung cancer, they were actually associated with increased rates



Downloaded for Anonymous User (n/a) at Egyptian Knowledge Bank from ClinicalKey.com by Elsevier on March 10, 2024. For personal use only. No other uses without permission. Copyright ©2024. Elsevier Inc. All rights reserved.

**Fig. 51.9 Pellagra. A** Hyperpigmentation and desquamation of the dorsal aspects of the hands and forearms. The shellac-like scale is seen best on the forearms. **B** Striking hypopigmentation with peripheral desquamation of the sun-exposed area of the chest in a man from sub-Saharan Africa. *B, Courtesy Rosemarie Moser, MD.*

of lung cancer[19]. The reported association of oral isotretinoin and topical tretinoin with increased mortality in smokers remains controversial[20].

Toxicity due to high doses of water-soluble vitamins (i.e. B vitamins, vitamin C) is rarely seen, as these compounds are rapidly excreted via the urine. While not an excess issue, ingestion of biotin to possibly improve hair and nails can interfere with biotin-streptavidin-based cardiac troponin, β-hCG, parathyroid, and thyroid (TSH, T3, T4) immunoassays.

### Vitamin D

Vitamin D plays a role in the absorption of calcium and phosphorus, helping to maintain normal serum levels of these minerals (Fig. 51.11). Vitamin D also functions as an antiproliferation and prodifferentiation hormone, but its exact role is not known[10]. Although a possible association of vitamin D deficiency with cutaneous disorders such as alopecia areata, atopic dermatitis, and psoriasis has been suggested, to date there are no known cutaneous signs of vitamin D deficiency. In addition, the Institute of Medicine (IOM) found no strong evidence to support a role for vitamin D supplementation for any medical condition other than bone health[21].

With the exception of individuals with sarcoidosis, the preferred method for assessing vitamin D status is measurement of total serum levels of 25-hydroxyvitamin D. While secondary hyperparathyroidism can influence the 1,25-dihydroxyvitamin D assay, this is not the case with the 25-hydroxyvitamin D assay. In addition, 25-hydroxyvitamin D has a longer half-life (2 weeks) and therefore is thought to better reflect body stores[18,22]. Currently, although a consensus is lacking, vitamin D *deficiency* is defined by most experts as a serum level of 25-hydroxyvitamin D that is <12 ng/ml (30 nmol/l), and vitamin D *insufficiency* as circulating levels of 12–20 ng/ml (30–50 nmol/l) (see Table 51.2).

Based upon these levels, it is estimated that one billion people worldwide have either deficient or insufficient levels of vitamin D[23]. Depending upon the study, ~50%–60% of nursing home residents, the elderly, and hospitalized patients in the US are deficient in vitamin D[23]. Decreased levels of 25-hydroxyvitamin D (<20 ng/ml) were also observed in half of US Hispanic or Black adolescents and White preadolescent girls[22]. In addition, ~50% of Black and 55% of White infants have vitamin D deficiency, while over 90% of infants in Iran, Turkey, and India have vitamin D deficiency.

While the IOM recommends a daily intake of vitamin $D_3$ of 400 IU/day (0–12 months of age), 600 IU/day (1–70 years of age), and 800 IU/day (>70 years of age), some experts have advocated 1000 IU/day for children or adolescents and 1500–2000 IU/day for adults (unless there are contraindications)[18,21,23]. All of these doses are below the age-dependent, tolerable, upper daily limits of 1000–4000 IU for infants and children (up to 18 years old) and 4000 IU for adults[23], with the range reflecting the current lack of a consensus regarding the upper daily limit. Vitamin $D_3$ (cholecalciferol; animal diet source) is viewed as nutritionally superior to vitamin $D_2$ (ergocalciferol; plant source) and therefore is regarded as the preferred form for supplementation and for fortifying foods. Although it is difficult to obtain enough vitamin $D_3$ from dietary sources alone, patients should be made aware of vitamin D-rich foods such as fatty fish, beef liver, cheese, egg yolks, mushrooms that have been exposed to ultraviolet light, and fortified foods[23].

An endogenous source of vitamin D production also exists, initiated with the conversion of 7-dehydrocholesterol to provitamin $D_3$ when skin is exposed to ultraviolet B radiation (see Fig. 51.11). It is thought that typically over 90% of vitamin D is produced via UVB exposure; however, the skin's ability to synthesize vitamin D diminishes with age and it is reduced in individuals with darker skin phototypes. The balance between sun protection (to prevent photodamage and cutaneous malignancies) and the risk of vitamin D deficiency has become a matter of debate. As effects of vitamin D, beyond calcium homeostasis and bone mineralization, have become increasingly recognized, the debate has intensified. For example, immunomodulatory effects via the innate immune system have been reported, as has an association between vitamin D deficiency and an increased risk of several internal malignancies[21]. While there are studies that refute the latter as well as no direct evidence linking sunscreen use with vitamin D deficiency[20,24], it is prudent to recommend that patients who are limiting sun exposure and/or have risk factors for the development of vitamin D deficiency ingest the daily recommended amount of vitamin $D_3$ (see Tables 51.2 & 51.3).

## *Trace elements*

Trace elements and minerals constitute ~3% of body weight at birth and 4% in adults. Based upon animal studies, 15 trace elements have been identified as essential for health: *iron*, *zinc*, *copper*, *chromium*, *selenium*, *iodine*, *fluoride*, *manganese*, *molybdenum*, *cobalt*, nickel, tin, silicon, vanadium, and arsenic (in very small doses). There is compelling evidence that the first 10 (in italics) are essential nutrients in humans. They serve multiple cellular functions including as cofactors for enzymes and as prosthetic groups in metalloproteins. An example of the latter is the complexing of iron and protoporphyrin IX via ferrochelatase to form heme[4]. Deficiency syndromes related to essential trace elements, other than iron, zinc, copper, iodine or cobalt, were not recognized until more recently. Explanations include the exceedingly small requirements for these trace elements, their ubiquitous nature in foodstuffs[4], and the lack of routine laboratory assays. Only trace elements of dermatologic importance will be discussed in this chapter.

### Zinc

Zinc is one of the most important trace elements in humans, playing a critical role in the function of more than 200 zinc-dependent metalloenzymes that regulate lipid, protein, and nucleic acid synthesis and degradation. Zinc can be found in human breast milk, animal-based foods, shellfish, legumes, and green leafy vegetables. There is evidence to suggest that zinc plays a role in enhancing wound healing as well as immune function[25] and this may explain the poor wound healing and



Downloaded for Anonymous User (n/a) at Egyptian Knowledge Bank from ClinicalKey.com by Elsevier on March 10, 2024. For personal use only. No other uses without permission. Copyright ©2024. Elsevier Inc. All rights reserved.

| VITAMIN EXCESS IN ADULTS AND CHILDREN | | | | |
|---|---|---|---|---|
| | | Clinical manifestations | | |
| **Vitamin** | **Mechanism of toxicity** | **Cutaneous** | **Systemic** | **Comments** |
| **A** | • Chronic intake of >25 000 IU vitamin A per day<br>• Ingestion of polar bear liver<br>• Coadministration with other retinoids | • Cheilitis<br>• Xerosis with pruritus<br>• Exfoliative dermatitis<br>• Alopecia | • Painful swelling of the long bones in young children<br>• Elevated hepatic enzymes<br>• Skeletal hyperostosis<br>• Calcification of extraspinal tendons and ligaments<br>• Pseudotumor cerebri<br>• Lethargy, anorexia | • Assessment by serum concentrations – unreliable<br>• Similar side effects as oral retinoids (see Ch. 126)<br>• Treatment – immediate discontinuation |
| **Beta-carotene** (natural provitamin of vitamin A) | • Carotenemia – high intake of carrots & yellow squash, including as baby food<br>• Lycopenia – high intake of tomatoes, gac, papaya, pink guava, & other fruits<br>• Inability to convert β-carotene to vitamin A (e.g. hypothyroidism, diabetes, anorexia nervosa) | • Yellow–orange discoloration (Fig. 51.10) due to deposition of carotenes/lycopenes in areas with:<br>– the thickest layer of stratum corneum (palms & soles)<br>– abundant sebaceous glands (nasolabial folds, forehead)<br>• Carotenoderma usually appears when carotene levels are 3–4× normal | • None | • Skin discoloration slowly disappears after altering diet<br>• Measurement of serum carotenoids (normal range: 0.4–1.5 mg/l) differentiates this disorder from jaundice, in which mucous membranes have a yellow color (most apparent in sclerae) |
| **D** | • >50 000 IU/day of oral supplementation | • None | • Nausea, vomiting<br>• Poor appetite<br>• Diarrhea, constipation<br>• Weakness<br>• Nephrolithiasis, nephrocalcinosis<br>• Hypercalcemia, hypercalciuria, hyperphosphatemia | • NOT caused by excessive exposure to UVR (previtamin $D_3$ and vitamin $D_3$ inactivated by sustained exposure of skin to heat)<br>• Tolerable upper limit for adults is 2000–4000 IU/day[6] |
| **E** | • High supplement doses | • Petechiae, ecchymoses | • May reduce platelet aggregation<br>• Interferes with function of vitamin K | • Drug–drug interactions with warfarin (increased anticoagulant effect) and antiplatelet agents (enhanced effect) (see Ch. 133)<br>• High doses of vitamin E (>400 IU/day) may reduce platelet aggregation |
| **K** | • None | • None | • None | • Side effects at sc injection sites:<br>– early: erythematous plaque, often annular (see Ch. 21)<br>– late: morpheaform plaque (Texier disease) |
| **C** | • Excessively high doses of oral supplements | • None | • GI upset<br>• Osmotic diarrhea<br>• Nephrolithiasis (oxalate renal calculi) | • Abrupt discontinuation of excessive vitamin C intake can also lead to scurvy |
| **$B_3$** (niacin, nicotinic acid) | • Excessively high doses of oral supplements | • Flushing, pruritus, xerosis<br>• Acanthosis nigricans | • Dyspepsia<br>• Hepatic failure<br>• Hyper- or hypoglycemia<br>• Hyperuricemia<br>• Hypothyroidism | |
| **$B_6$** | • Long-term oral doses of >200 mg/day | • Photosensitivity | • Loss of proprioception<br>• Painful sensory neuropathy | |
| **$B_7$** (biotin) | | | | High levels of biotin may interfere with biotin-streptavidin-based cardiac troponin, β-hCG, parathyroid, and thyroid (TSH, T3, T4) immunoassays |

**Table 51.4 Vitamin excess in adults and children.** GI, gastrointestinal; SC, subcutaneous; UVR, ultraviolet radiation. Adapted in part from refs 5–7.

increased susceptibility to cutaneous infections observed in patients with chronic zinc deficiency. Due to its antioxidant properties, zinc might protect the skin against UV-induced damage[26].

Patients with zinc deficiency can develop erythema, scale-crusts and erosions, especially periorally, acrally, and in the anogenital region (Fig. 51.12); occasionally, vesicles or bullae are seen as well as psoriasiform plaques. Zinc deficiency may also lead to alopecia, paronychia, onychodystrophy, blepharitis, conjunctivitis, stomatitis, and angular cheilitis. Diarrhea, depression (apathy), and dermatitis (erosive) are sometimes considered the triad of zinc deficiency, but the complete triad is seen in only 20% of patients. Superimposed cutaneous infections with *Candida* spp. and staphylococci are very common. Patients are typically irritable and sleep poorly; children with chronic zinc deficiency may experience growth retardation and/or develop hypogonadism. If treatment is not initiated, death may ensue.

Zinc deficiency can be either acquired or inherited as an autosomal recessive disorder, known as acrodermatitis enteropathica (AE). The latter is due to mutations in the gene that encodes the transmembrane



Downloaded for Anonymous User (n/a) at Egyptian Knowledge Bank from ClinicalKey.com by Elsevier on March 10, 2024. For personal use only. No other uses without permission. Copyright ©2024. Elsevier Inc. All rights reserved.

**Fig. 51.10 Carotenoderma.** The patient's legs are noticeably orange when compared to the photographer's hand.

zinc transporter SLC39A4 which is expressed in the intestine and kidney. Clinical manifestations usually appear within 1 to 2 weeks after weaning from breast milk, or at 4 to 10 weeks of age if bottle-fed. Of note, transient neonatal zinc deficiency can develop in breastfed babies when breast milk contains low levels of zinc due to dysfunction of SLC30A2, the zinc transporter in the breast (in the mother). In addition, infants and children with cystic fibrosis can develop zinc deficiency (Fig. 51.13). This deficiency should be considered in children who have treatment-resistant seborrheic dermatitis or anogenital dermatitis.

There are several risk factors for developing acquired zinc deficiency, including alcohol use disorder, anorexia nervosa, diets high in mineral-binding phytate (Middle Eastern diets), and vegan diets. Of note, vegan diets can also lead to low levels of long-chain n-3 (omega-3) fatty acids, calcium, vitamin D, and vitamin $B_{12}$[27]. Intestinal malabsorption often results in multiple deficiencies, including zinc. In addition, zinc deficiency can be seen in association with pregnancy, HIV disease, chronic renal failure, sickle cell disease, and drugs (e.g. penicillamine). Especially when combined with other risk factors, drugs such as diuretics and antacids can result in zinc deficiency while quinolones and tetracyclines can reduce absorption of zinc supplements.

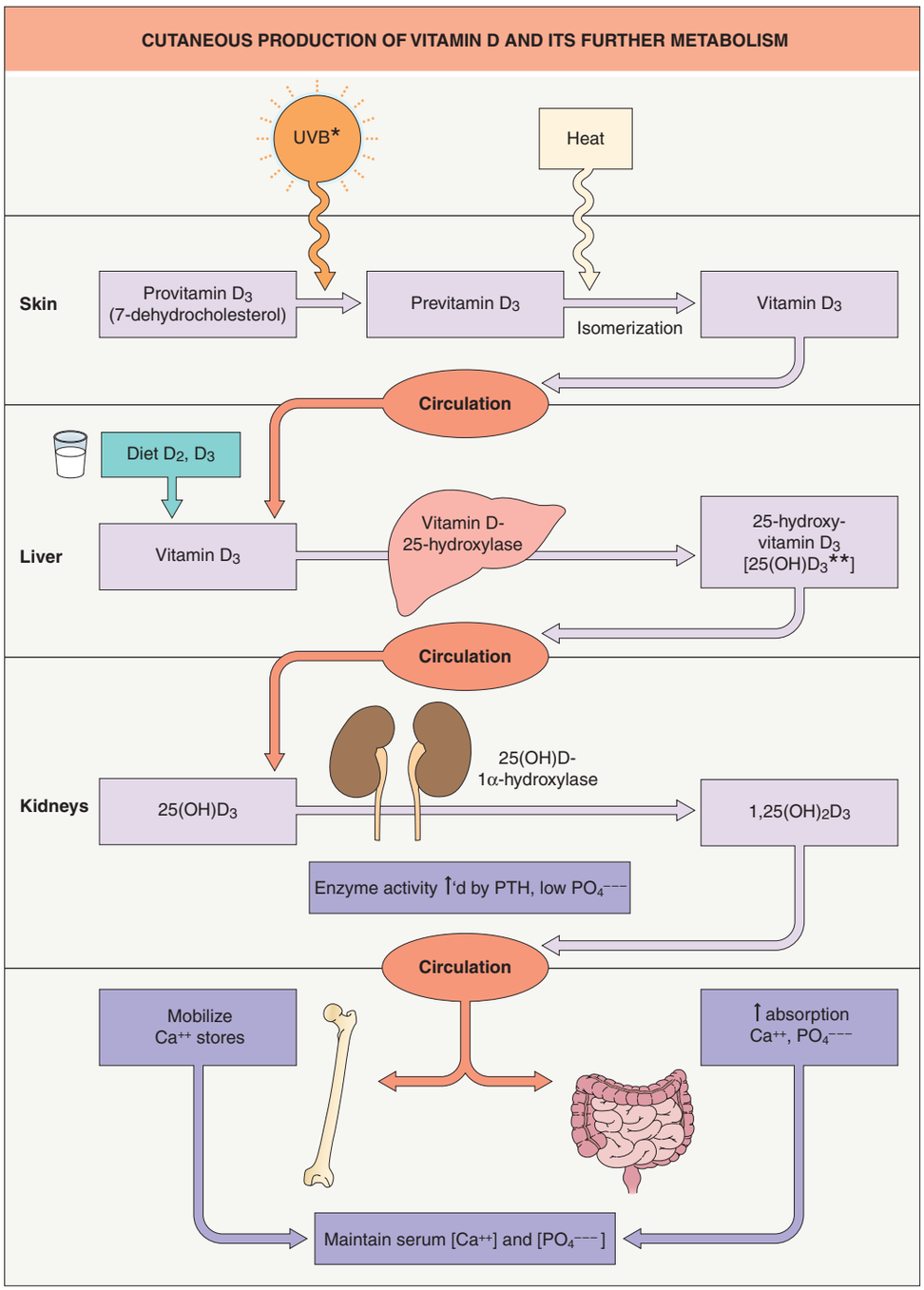


**Fig. 51.11 Cutaneous production of vitamin D and its further metabolism.** During exposure to ultraviolet B radiation, 7-dehydrocholesterol within the skin is converted to previtamin $D_3$, which is then immediately converted to vitamin $D_3$ in a heat-dependent process[22]. Of note, the heat from excessive sunlight exposure can degrade previtamin $D_3$ and vitamin $D_3$ into inactive photoproducts. Both forms of vitamin D ($D_3$ and $D_2$) are biologically inactive and they require activation in the liver and then the kidney. After binding to carrier proteins, vitamin D is transported to the liver, where it is enzymatically hydroxylated to 25-hydroxyvitamin D [25(OH)D], the major circulating form of vitamin D. 25-hydroxyvitamin D is then converted into its active form, 1,25-dihydroxyvitamin D [$1,25(OH)_2D$], within the kidney by the enzyme 1α-hydroxylase. Of interest, this final hydroxylation step can also occur in keratinocytes when the enzyme CYP27B1 is upregulated in response to wounding or by Toll-like receptor (TLR) activation from microbial-derived ligands[17]. Serum levels of phosphorus, calcium, and fibroblast growth factor 23 can either increase or decrease renal production of $1,25(OH)_2D$. $1,25(OH)_2D$ decreases its own synthesis via feedback inhibition and decreases the synthesis and secretion of parathyroid hormone by the parathyroid glands. $1,25(OH)_2D$ also enhances intestinal calcium absorption in the small intestine by interacting with the vitamin D receptor–retinoic acid X receptor complex (VDR-RXR) to enhance the expression of the epithelial calcium channel and calbindin-D 9 K, a calcium-binding protein. In addition, $1,25(OH)_2D$ is recognized by its receptor in osteoblasts, leading to a series of events that maintain calcium and phosphorus levels in the blood which in turn promotes mineralization of the skeleton. *Most effective wavelength = 300 ± 5 nm. **Measurement of this form most commonly done to assess vitamin D status.



Downloaded for Anonymous User (n/a) at Egyptian Knowledge Bank from ClinicalKey.com by Elsevier on March 10, 2024. For personal use only. No other uses without permission. Copyright ©2024. Elsevier Inc. All rights reserved.

**Fig. 51.12 Zinc deficiency – inherited and acquired forms.** Erythema with erosions and scale-crust that is often shellac-like favors the perioral (**A**), acral (**B–D**), and anogenital (**E**, **F**) regions. Pustular paronychia can also be seen (**B**). The degree of involvement can vary from subtle to striking and may mimic other types of "nutritional dermatitis" (see Fig. 51.13), necrolytic migratory erythema, and more common disorders such as seborrheic dermatitis and psoriasis. The superficial erosions are a reflection of necrosis of the upper portion of the epidermis (**G**). *A–C,F, Courtesy Julie V. Schaffer, MD; G, Courtesy Lorenzo Cerrroni, MD.*

The histologic finding of epidermal necrosis (see below) plus low serum alkaline phosphatase (a zinc-dependent enzyme) and zinc levels suggest zinc deficiency; the normal reference range for zinc is 70–150 mcg/dl (10.7–22.9 mcmol/l). Reduced zinc levels can occasionally lag behind cutaneous manifestations. Some patients with necrolytic acral erythema also have reduced zinc levels (and improve with zinc supplementation) while others have associated hepatitis C viral infections[28]. Likewise, zinc levels can be normal or reduced in patients with necrolytic migratory erythema (NME) as well as EGFR inhibitor-induced NME-like eruptions.

Cutaneous and systemic manifestations respond dramatically to supplementation with elemental zinc (1–2 mg/kg/day in the acquired forms and 3 mg/kg/day for AE). There are several forms of commercially available zinc supplements including zinc sulfate, zinc gluconate, and zinc acetate, and they contain variable amounts of elemental zinc, e.g. 220 mg zinc sulfate tablets contain 50 mg of elemental zinc. Patients with persistent malabsorption syndromes and AE require lifelong zinc supplementation, along with regular serum zinc determinations. Of note, ingestion of excessive amounts of zinc can decrease copper absorption and lead to copper deficiency.

## Copper

Copper is an essential trace element that is required for the function of a number of enzymes, e.g. tyrosinase, lysyl oxidase. In the bloodstream, 90% of copper is associated with ceruloplasmin, and the remainder is bound to other plasma proteins, primarily albumin. Acquired copper deficiency is rare, but it has been reported in infants receiving milk low in copper, in protein–energy malnutrition, and as a consequence of excessive zinc intake. Symptoms include anemia, neutropenia, and failure to thrive. Cutaneous findings are limited to rare reports of pigmentary dilution of the skin and hair.

Menkes disease, also known as kinky hair disease, is an X-linked recessive condition characterized by defective copper absorption with low copper levels in the blood, liver, and hair. Affected infants may appear normal and develop normally until 2 to 3 months of age, when they gradually manifest failure to thrive, lethargy, hypothermia, and hypotonia. In addition to seizures and developmental delay, patients may also have anemia and bony abnormalities (similar to those in scurvy). Arteriography demonstrates tortuosity and elongation of arteries, a reflection of immature elastin[29]. Decreased activity of several enzymes, including cytochrome C oxidase (in the brain), lysyl oxidase (in connective tissues and blood vessels), and ascorbic acid oxidase (in bones), may account for the associated clinical findings.

Pudgy cheeks, a cupid's bow of the upper lip, and horizontal eyebrows comprise the typical facies in Menkes disease[30]. However, a more obvious and characteristic finding is alopecia with abnormal hair shafts. There are 180° twists of the hair (pili torti), segmental shaft narrowing (monilethrix), and brush-like swellings of the hair shaft (trichorrhexis nodosa). Hairs are light in color, sparse (Fig. 51.14), fragile, and kinky. Patients may also have diffuse cutaneous pigmentary dilution due to decreased activity of tyrosinase, a copper-dependent enzyme. In addition, obligate female carriers may have patches of swirled



Downloaded for Anonymous User (n/a) at Egyptian Knowledge Bank from ClinicalKey.com by Elsevier on March 10, 2024. For personal use only. No other uses without permission. Copyright ©2024. Elsevier Inc. All rights reserved.

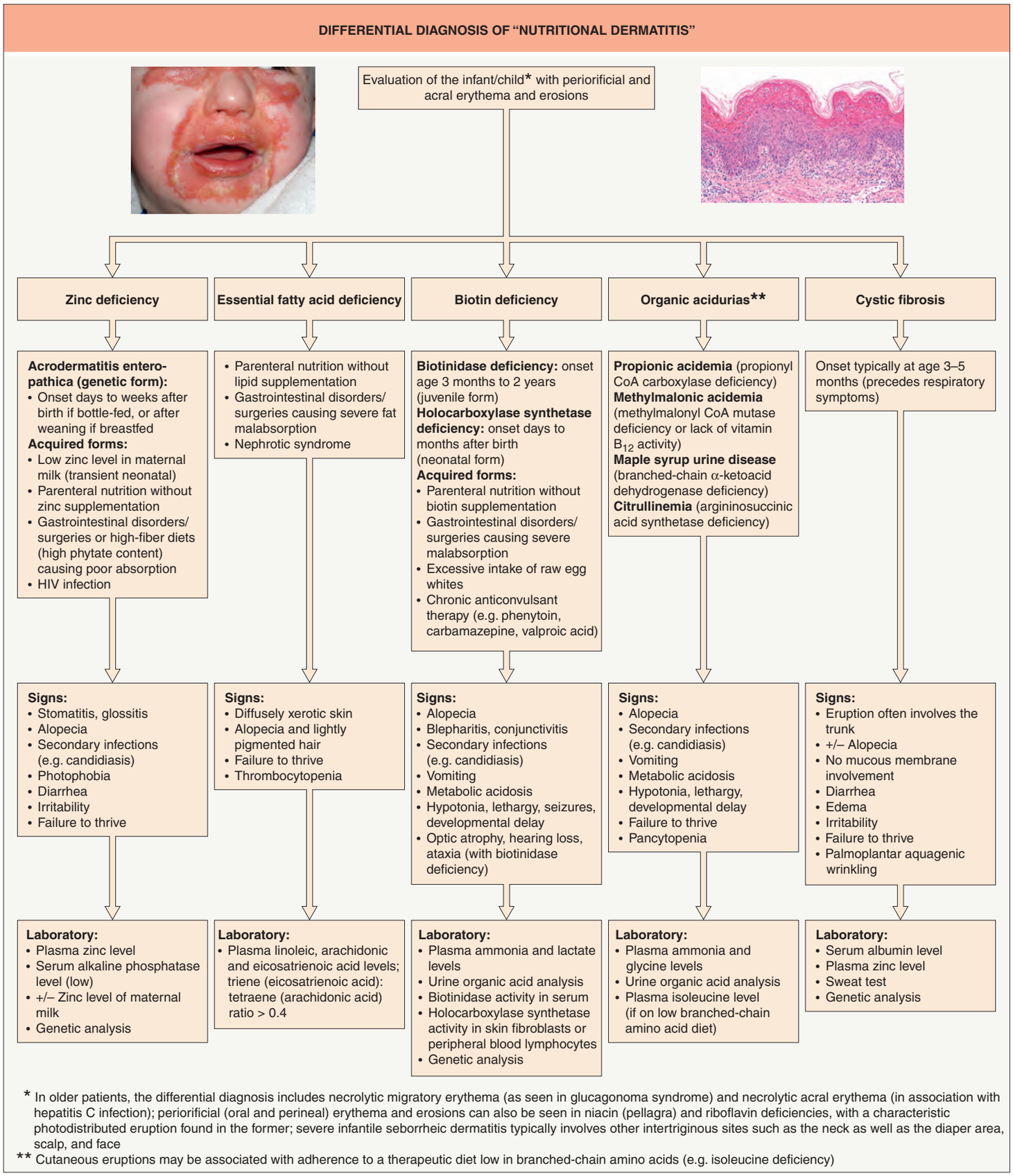


**Fig. 51.13 Differential diagnosis of "nutritional dermatitis" (in addition to exogenous protein–energy malnutrition).** *Courtesy Julie V. Schaffer, MD; Photomicrograph Courtesy Luis Requena, MD.*

hypopigmentation or pili torti along the lines of Blaschko, as a result of lyonization.

The clinical features, low serum levels of copper and ceruloplasmin, and microscopic hair shaft findings establish the diagnosis. Infants with Menkes disease have a poor prognosis, with a life expectancy of 3 to 5 years and progressive deterioration leading to death. Treatment with copper histidine is unsuccessful in the majority of patients, but those with mutations leading to reduced, but not absent, copper transport may be more likely to respond to early intervention. Mutations in *ATP7A*, which encodes a copper-transporting ATPase, lead to Menkes



Downloaded for Anonymous User (n/a) at Egyptian Knowledge Bank from ClinicalKey.com by Elsevier on March 10, 2024. For personal use only. No other uses without permission. Copyright ©2024. Elsevier Inc. All rights reserved.

**Fig. 51.14 Menkes disease.** This child has the characteristic pale skin and sparse kinky hair. *Courtesy Ramón Ruiz-Maldonado, MD.*

disease (as well as occipital horn syndrome; see Ch. 97); therefore, prenatal diagnosis is possible.

Copper toxicity can be acquired or inherited. The acquired form usually results from the ingestion of excessive amounts of copper (e.g. milk boiled in eroded copper pots) and this leads to gastrointestinal symptoms and, occasionally (in predisposed individuals), childhood cirrhosis. The inherited form is Wilson disease, an autosomal recessive disorder characterized by an accumulation of copper within internal organs, in particular the liver, cornea, and brain. Affected individuals have mutations in *ATP7B* which also encodes a copper-transporting P-type ATPase. Dysfunction of this protein leads to an impairment of both intrahepatic trafficking and biliary excretion of copper[30].

Because daily copper intake exceeds the body's requirements, an effective means of excreting excess copper is crucial. This is accomplished by ATP7B, which mediates both copper secretion into plasma (coupled with ceruloplasmin synthesis) and its excretion into bile. When ATP7B is dysfunctional, the presence of excess copper within tissues induces free-radical reactions and lipid peroxidation. Resultant hepatic damage leads to steatosis, inflammation, cirrhosis, and eventually liver failure[31].

The diagnosis of Wilson disease is established by the detection of low serum ceruloplasmin, increased urinary copper excretion, increased hepatic copper content, and/or genetic testing. The clinical hallmarks of Wilson disease are hepatomegaly, cirrhosis, Kayser–Fleischer corneal rings, and neurologic symptoms (dysarthria, dyspraxia, ataxia, and parkinsonian-like extrapyramidal signs).

The chelating agents penicillamine and trientine, which facilitate excretion of copper, are approved for the treatment of Wilson disease. Oral zinc acetate can be prescribed for pre-symptomatic patients or as maintenance therapy, as it blocks intestinal absorption via induction of copper-binding metallothionein within enterocytes, thereby preventing serosal transfer.

### Selenium

Selenium, in the form of selenocysteine, is an essential component of several enzymes, including those involved in thyroid hormone metabolism and protection against oxidative damage (e.g. glutathione peroxidase). Deficiency of selenium typically results in a cardiomyopathy as well as muscle pain and weakness due to muscle degeneration; there may also be signs and symptoms of hypothyroidism. Cutaneous manifestations include hypopigmentation of the skin and hair (considered early signs), leukonychia, and xerosis, all of which respond to selenium replacement[32]. There was also a report of erythematous scaly papules and plaques involving the cheeks, hips, thighs, and popliteal fossae, along with erosions in the diaper area[33]. Elevated serum levels of creatine kinase and transaminases are often present in selenium deficiency as well.

Selenium deficiency has been reported in patients receiving total parenteral nutrition and in those who live in areas where the soil content of selenium is poor[34]. Low serum levels of selenium and glutathione peroxidase activity are indicative of selenium deficiency. The recommended replacement dosage in selenium-deficient patients is a maximum of 100–200 mcg/day, and the Recommended Dietary Allowance (RDA) is 55 mcg/day for adults and 15 mcg/day for infants.

Although controversial, over-supplementation can occur due to reported beneficial cardiovascular and anticancer effects of selenium[35]. If supplements are taken, they should not exceed 200 mcg/day. Excessive selenium ingestion (e.g. supplements, Brazil nuts, selenium-enriched green tea) can produce selenosis in humans, leading to a peripheral neuropathy, dermatitis, facial flushing, alopecia, discolored or brittle nails, nausea and vomiting as well as a garlic-like breath odor. The use of selenium sulfide shampoo in large areas of eroded or ulcerated skin may lead to excessive absorption, with loss of appetite and tremor.

## Anorexia Nervosa and Bulimia (Nervosa)

Anorexia nervosa and bulimia nervosa are eating disorders characterized by starvation, excessive exercise, self-induced vomiting, and/or abuse of medications (e.g. laxatives, diuretics). Both can result in primary and secondary nutritional deficiencies. Anorexia nervosa is a persistent unwillingness or inability to maintain adequate body weight, whereas patients with bulimia typically binge-eat then purge or fast. These disorders occur most commonly in adolescent girls and young adult women, but can affect both sexes and all age groups. Skin disorders, either real or perceived, are common in these patients and women in particular report a greater dissatisfaction with the appearance of their skin when compared to a similar cohort[36].

The dietary changes and starvation associated with anorexia nervosa and bulimia can lead to telogen effluvium, lanugo-like hair, xerosis, generalized pruritus, carotenoderma (see Fig. 51.10), and hyperpigmentation. In addition, patients can develop acrocyanosis, perniosis, and livedo reticularis. Signs of specific nutritional deficiencies (e.g. pellagra, scurvy) may be present, as well as poor wound healing, seborrheic dermatitis, and edema[37]. Additional clues to the diagnosis include petechiae, interdigital intertrigo, paronychia, and particularly calluses or scars on the knuckles or dorsal surface of the hand (Russell's sign) due to repeated self-induced vomiting over prolonged periods of time (Fig. 51.15). Patients with bulimia may also have enlarged salivary glands and erosion of their tooth enamel. Psychiatric and nutritional support must be instituted as severe malnutrition is common.

## Obesity

Obesity, whether acquired or inherited, is defined as a body mass index (BMI; measured in $kg/m^2$), that is >30; the latter has been found to correlate with high levels of the adipokine leptin[38]. Genetic disorders such as Prader–Willi, Bardet–Biedl, Alström, and Wilson–Turner syndromes have been associated with childhood-onset obesity. In addition, endocrine disorders such as Cushing disease, Cushing syndrome, and insulin resistance include obesity amongst their clinical manifestations.

Acquired obesity is at epidemic proportions in both adults and children in industrialized nations. Although paradoxical, it is a functional malnutrition due to the consumption of high-caloric foods that are low in nutrients. Obesity is a systemic disease, as evidenced by an increased incidence of hypertension, hyperglycemia and hyperlipidemia, components of the metabolic syndrome (see Table 53.5), as well as atherosclerotic cardiovascular disease and premature death. Cutaneous manifestations are nonspecific, but some of the more common findings, such as acanthosis nigricans, appear to be related to insulin resistance (see Fig. 51.15)[39].

## Bariatric Surgery and Gastrointestinal Malabsorption

The increase in acquired obesity has led to an increase in the number and types of bariatric surgery performed. Due to subsequent alterations in gastrointestinal absorption, post-bariatric surgery patients are at risk for developing nutritional deficiencies. Two of the more commonly performed surgeries are laparoscopic adjustable gastric banding and the Roux-en-Y gastric bypass. Because the normal absorptive surface is left intact with the former, nutrient deficiencies in these patients are rare. On the other hand, the Roux-en-Y gastric bypass procedure reduces stomach size and, as a result, there are lower levels of intrinsic factor, gastrin, hydrochloric acid, and pepsinogen, which lead to a reduction in protein digestion. The Roux-en-Y procedure also decreases the physical grinding of food that typically helps to release vitamins and minerals. Abnormally low levels of micronutrients, such as iron, zinc, copper, and vitamins A, E, $B_9$ (folate), and $B_{12}$, may be seen in these patients, and long-term monitoring is required, as it may take months or years for signs and symptoms to appear[40,41].



Downloaded for Anonymous User (n/a) at Egyptian Knowledge Bank from ClinicalKey.com by Elsevier on March 10, 2024. For personal use only. No other uses without permission. Copyright ©2024. Elsevier Inc. All rights reserved.

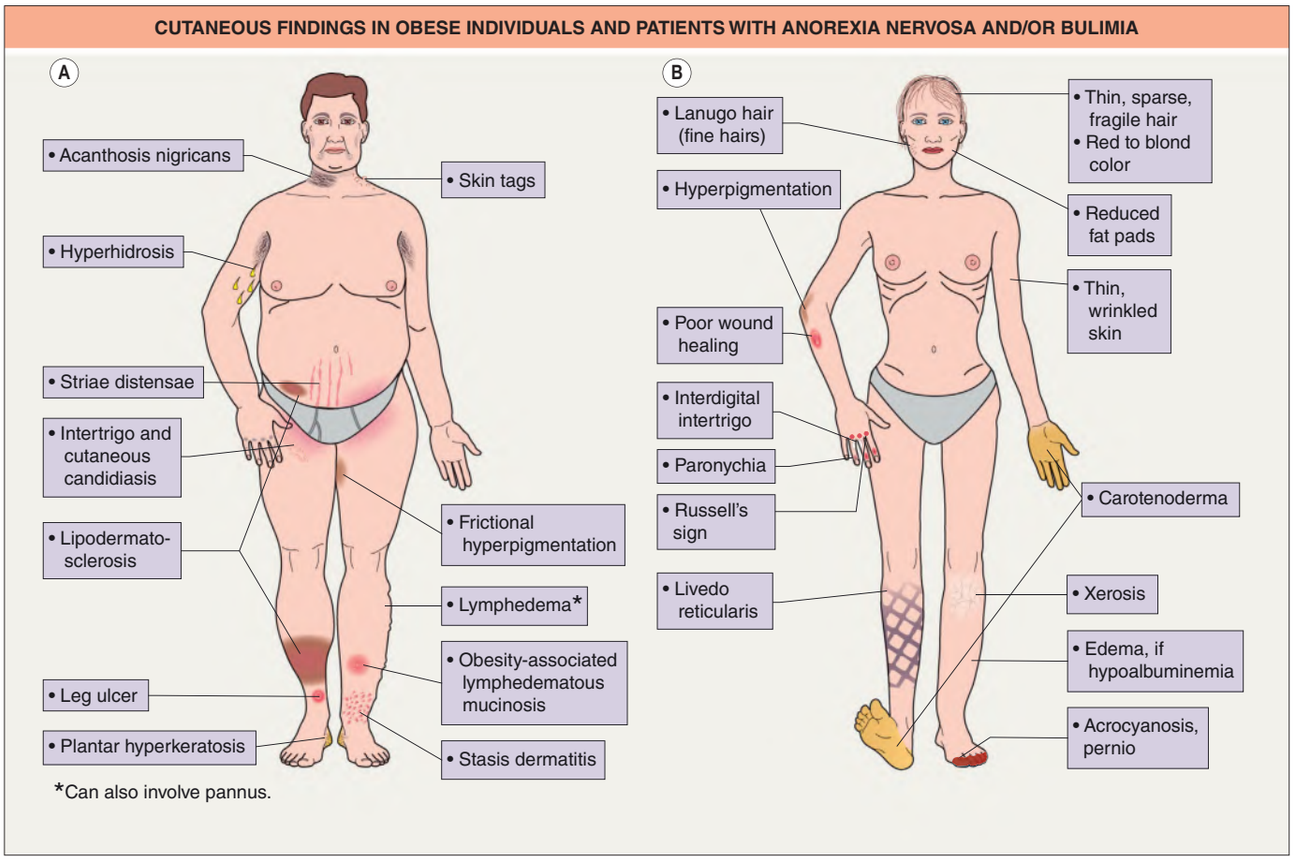


**Fig. 51.15 Cutaneous findings in obese individuals (A) and patients with anorexia nervosa and/or bulimia (B).** Russell's sign consists of calluses or scars on the knuckles or dorsal surface of the hand due to repeated self-induced vomiting over prolonged periods of time. See Fig. 51.2 for signs of nutritional deficiencies.

In disorders such as Crohn disease that are associated with gastrointestinal malabsorption, at least 50% of patients may have low plasma concentrations of vitamin C, copper, niacin, and zinc[42].

## PATHOLOGY

Nutritional deficiencies generally occur in combination; therefore, the resultant pathologic changes are often very variable. Although nutritional diseases have been better studied biochemically than structurally, there are several helpful histologic clues, including necrosis of the upper one-third of the epidermis (see Fig. 51.12G). This distinctive reaction pattern has been reported in pellagra, acrodermatitis enteropathica, acquired zinc deficiency, and necrolytic migratory erythema. In the early stages, there is pallor and ballooning of the upper half of the epidermis. This stage is followed by the development of acanthosis, with confluent hyperkeratosis and degenerative features of the upper epidermal layers. In the late stages, the pallor of the upper epidermis is usually missing[43]. In protein–energy malnutrition, nonspecific histologic features are seen, such as epidermal atrophy and hyperkeratosis.

Hair is a superb model of growth and differentiation. In some patients, histologic study of the hair matrix and hair shaft may provide evidence of moderate to severe degrees of protein–energy malnutrition[44].

## DIFFERENTIAL DIAGNOSIS

Nutritional dermatoses rarely result from the deficiency of a single nutrient, element, or vitamin as multiple deficiencies often coexist. A high index of suspicion is required in that clinical manifestations are often nonspecific and, in mild to moderate deficiencies, somewhat subtle. A few specific deficiencies do have characteristic mucocutaneous and systemic features that can be accurately recognized by the experienced clinician. Suspected deficiencies can usually be confirmed via laboratory analysis (see Table 51.2), and they readily respond to the administration of the deficient nutrient, element, and/or vitamin.

## TREATMENT

The treatment of nutritional diseases must be individualized, taking into account the likelihood of multiple deficiencies of both macro- and micronutrients. The recommended treatment for specific nutritional diseases is reviewed in this chapter, but management frequently requires a multidisciplinary approach.

**Additional figures available in our eBook (see inside front cover for access code).**

**eFig. 51.1 Kwashiorkor.** This child's arm has edema and superficial epidermal necrosis with a "flaky paint" appearance. *Courtesy Ramón Ruiz-Maldonado, MD*.

**eFig. 51.2 Kwashiorkor.** Edema, ulceration, and shellac-like scale that resembles peeling paint.

**eFig. 51.3 Kwashiorkor.** Edema and shellac-like scale in a child on a vegan diet. *Courtesy Jeff Gehlhausen, MD, PhD*.

**eFig. 51.4 Vitamin A deficiency.** Blindness due to vitamin A deficiency and corneal scarring. *Courtesy Peter Ehrnstrom, MD*.

**eFig. 51.5 Pellagra.** The photodistribution of erythema (**A**), erythema plus shiny desquamation (**B**), and erythema plus bullae (**C**) is apparent. Note the sparing under the watchband and shoes. *Courtesy Luis Requena, MD*.



Downloaded for Anonymous User (n/a) at Egyptian Knowledge Bank from ClinicalKey.com by Elsevier on March 10, 2024. For personal use only. No other uses without permission. Copyright ©2024. Elsevier Inc. All rights reserved.

**eFig. 51.6 Pellagra.** Hyperpigmented desquamation of the distal lower extremity. Note the shiny shellac-like appearance on the lateral ankle.

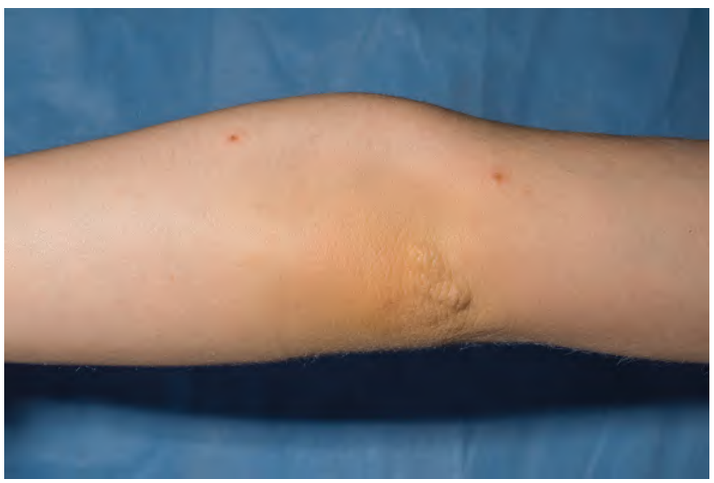

**eFig. 51.7 Carotenoderma.** Yellow–orange discoloration of the extensor elbows in an 8-year-old whose diet consisted primarily of pureed carrots due to numerous dental extractions. *Courtesy Edward Cowen, MD.*

**eFig. 51.8 Acrodermatitis enteropathica. A** Erosive plaques of the buttocks and perianally. **B** Erosive plaques of the toes. *Courtesy Julie V. Schaffer, MD.*

**eFig. 51.9 Acrodermatitis enteropathica. A** Perioral and perinasal erosive plaques with desquamation and crusting in an infant. **B** Erythema with erosions and scale-crust that favors acral sites. *A, Courtesy A. Hernández-Martín, MD.*

**eFig. 51.10 Acquired zinc deficiency.** Erythematous plaques with scaling and a few erosions near one oral commissure in an adult. The latter are a clue that this is not simply seborrheic dermatitis. *Courtesy Luis Requena, MD.*



Downloaded for Anonymous User (n/a) at Egyptian Knowledge Bank from ClinicalKey.com by Elsevier on March 10, 2024. For personal use only. No other uses without permission. Copyright ©2024. Elsevier Inc. All rights reserved.

**eFig. 51.11 Acquired zinc deficiency. A, B** The findings within flexural areas are more subtle in this patient. **C** There is also nail dystrophy – thickening, yellow discoloration, loss of cuticle.

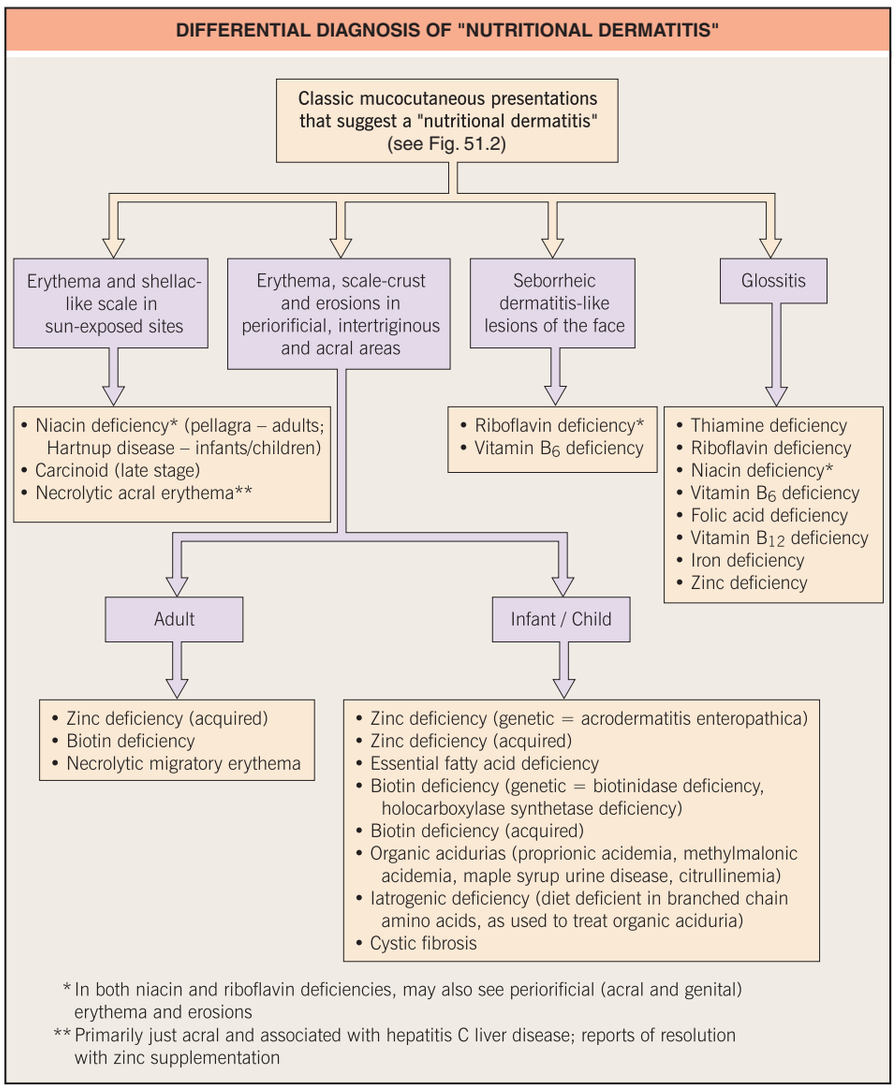


**eFig. 51.12 Differential diagnosis of "nutritional dermatitis".**



Downloaded for Anonymous User (n/a) at Egyptian Knowledge Bank from ClinicalKey.com by Elsevier on March 10, 2024. For personal use only. No other uses without permission. Copyright ©2024. Elsevier Inc. All rights reserved.